

**Module SM 508**

**OBJECTIVES**

- 1- To know types, pathophysiology, clinical presentations, different investigations of various forms of anemias and how to manage
- 2- To study various types of hematologic malignancies
- 3- To study the types, pathophysiology, clinical presentations of leukemias, investigations and lines of management
- 4- To study types, pathology, clinical presentations, investigations of lymphomas and approaches of treatment
- 5- To study surgical disorders of lymph nodes
- 6- to study the surgical importances of veins and venous disorders of the lower limbs and pharmacology of anticoagulation therapy
- 7- to study the surgical importances and diseases of the arterial system and their management
- 8- to study surgical disorders of common types of gangrene and diabetic infections of the lower limbs and management
- 9- to study the parasitological diseases of hematological importances

## APPROACH TO THE ANEMIAS, MICROCYTIC ANEMIA

### **Objectives**

The student will;

- 1) Know the basic pathophysiology underlying anemia
- 2) Understand the pathologic mechanisms of different types of anemia
- 3) Understand the clinical features of anemia
- 4) Understand the various causes of microcytic anemia
- 5) Know the basic physiology of iron metabolism
- 6) Understand the various causes of microcytic anemia
- 7) Understand the laboratory features of microcytic anemia
- 8) Understand the various treatment options for microcytic anemia

### **Definition**

Anemia is defined as a reduction in the number of circulating erythrocytes.

Any condition that can impair the production or increase the rate of destruction or loss of erythrocytes can result in anemia if the bone marrow is unable to compensate for the rate of loss of red blood cells.

### **Pathophysiology**

Normal Erythropoiesis

- A circulating erythrocyte under normal conditions has an average lifespan of approximately 120 days. It is a non-nucleated, nondividing cell in which more than 90% of the protein content is the oxygen-carrying molecule hemoglobin.
- The erythrocyte's sole responsibility is to deliver oxygen to the tissues of the body.
- The primary consequence of anemia is tissue hypoxia.
- Oxygen-sensing cells, which are thought to be located near the tip of the juxtamedullary region of the cortical labyrinths of the kidney, respond to local tissue hypoxia by increasing production of erythropoietin (EPO), the primary regulatory hormone for erythropoiesis.
- Hypoxia, as sensed in the kidney, results in increased production of EPO, which leads to increased erythrocyte production by the bone marrow. When the local tissue hypoxia is due to a reduction in the number of circulating erythrocytes, the amount of hemoglobin, and the consequent decreased total body oxygen-carrying capacity, the increased EPO produced by the kidney stimulates the bone marrow to produce increased numbers of erythrocytes to compensate for the existing deficiency of RBCs.
- When an increase in EPO levels in the circulation occurs in response to an acute onset of anemia, new proerythroblasts and normoblasts appear in the bone

marrow within 2 to 4 days, and new reticulocytes begin to appear in the peripheral blood within 3 to 7 days.

### **Pathogenesis of Anemias**

The basic mechanisms of anemia can be divided into:

- Conditions that result in accelerated destruction or loss of RBCs.
- Conditions in which the primary abnormality is impaired ability of the bone marrow to produce sufficient numbers of erythrocytes to replace the erythrocytes that are lost.

### **PATHOPHYSIOLOGIC CLASSIFICATION OF ANEMIAS CAUSED BY IMPAIRED PRODUCTION OF ERYTHROCYTES BY BONE MARROW**

<b><i><u>Erythropoietin (EPO) deficiency (normocytic anemias)</u></i></b>
❖ Renal insufficiency
<b><i><u>Quantitative deficiency of hematopoietic/erythroid progenitor cells (normocytic anemias)</u></i></b>
❖ Idiopathic bone marrow aplasia/hypoplasia
❖ Secondary bone marrow aplasia/hypoplasia (drugs, toxins, infections, radiation, malnutrition)
❖ Myelofibrosis (primary or secondary)
❖ Bone marrow replacement by neoplastic cells (myelophthisis)
<b><i><u>Impaired DNA synthesis</u></i></b>
❖ Cobalamin (vitamin B12) deficiency
❖ Folate deficiency
❖ Cancer chemotherapeutic drugs
<b><i><u>Impaired heme synthesis (microcytic anemias)</u></i></b>
❖ Iron deficiency
<b><i><u>Impaired globin synthesis in differentiating erythroid cells (microcytic anemias)</u></i></b>
❖ Thalassemias

Anemias Caused By Accelerated Destruction, Consumption(Hemolysis) , Or Loss Of Circulating Erythrocytes( Bleeding)

## **BLOOD LOSS**

- ❖ Acute: trauma
- ❖ Chronic: lesions of gastrointestinal tract, gynecologic disturbances

## **INCREASED RATE OF DESTRUCTION (HEMOLYTIC ANEMIAS)**

### **A. Intrinsic (intracorpuseular) abnormalities of RBCs**

#### **1. Hereditary**

- ❖ Disorders of RBC membrane cytoskeleton (e.g., spherocytosis, elliptocytosis)
- ❖ RBC enzyme deficiencies ( G6PD)
- ❖ Disorders of hemoglobin synthesis:
  - A) Deficient globin synthesis: thalassemia syndromes
  - B) Structurally abnormal globin synthesis (hemoglobinopathies): sickle cell anemia

#### **2. Acquired**

Membrane defect: paroxysmal nocturnal hemoglobinuria

### **B. Extrinsic (extracorpuseular) abnormalities**

#### **❖ Antibody mediated**

- a. Isohemagglutinins: transfusion reactions, erythroblastosis fetalis (Rh disease of the newborn)
- b. Autoantibodies: idiopathic (primary), drug-associated, systemic lupus erythematosus

#### **❖ Mechanical trauma to RBCs**

Microangiopathic hemolytic anemias: thrombotic thrombocytopenic purpura, disseminated intravascular coagulation

- ❖ Infections: malaria

## **Clinical Manifestations of Chronic Anemia**

- Weakness, fatigue, lethargy, decreased stamina, palpitations, dyspnea on exertion, and orthostatic light-headedness are common symptoms in patients with chronic anemia.
- Comorbid conditions, particularly with impaired blood supply or oxygenation of specific organs, may result in symptoms and signs secondary to organ-specific dysfunction.
- Anemic patients with previous myocardial dysfunction may have more pronounced edema, dyspnea, orthopnea, tachycardia, fatigue, and loss of stamina. In patients with coronary artery disease, anemia may result in the onset or worsening of angina or may precipitate myocardial infarction.
- New or worsening claudication may develop in anemic patients with significant peripheral arterial disease.

## **Physical signs**

- a) The most prominent general physical examination findings that may occur in patients with significant anemia include pallor of the skin, especially under the nails, and mucosal surfaces.
- b) Orthostatic hypotension, resting or orthostatic tachycardia, a systolic ejection murmur, increased prominence of the cardiac apical impulse, bounding pulses, and a wide pulse pressure.
- c) The presence of splenomegaly or a history of previous splenectomy raises the possibility of chronic hemolytic anemia.
- d) A right upper quadrant surgical scar or a history of gallstones or cholecystectomy (or both) should also raise the possibility of a chronic hemolytic state with the formation of bilirubin-containing gallstones

## **MICROCYTIC AND HYPOCHROMIC ANEMIAS**

### **Introduction**

The oxygen-carrying hemoglobin molecule executes the principal function of the mature erythrocyte. The hemoglobin content of erythrocytes is determined by the coordinated production of *globin protein, the heme porphyrin ring, and the availability of iron*. A deficiency in any of these three critical components of hemoglobin results in hypochromic and/or microcytic anemia.

## **IRON DEFICIENCY ANEMIA**

### **Epidemiology**

Iron deficiency is by far the most common cause of anemia worldwide and is among the most frequently encountered medical problems seen by primary care.

### **Pathophysiology**

- ❖ The majority of the approximately 4 g of iron in the adult human body is incorporated into hemoglobin (approximately 2100 mg) in erythrocytes, or myoglobin (approximately 300 mg) in muscle.
- ❖ Only a small amount of iron (3 to 7 mg) is freely circulating in plasma bound to transferrin, but this pool is kinetically very active.
- ❖ An average of about 1 to 2 mg of iron is normally lost per day, largely through mucosal sloughing, desquamation, and, in females of reproductive age, menstruation.

- ❖ Circulating plasma iron is complexed with the iron transport protein, transferrin. The transferrin iron complex is then taken up by erythroid precursors via the transferrin receptor.

### **Causes of Iron Deficiency**

#### **Increased demand for iron and/or hematopoiesis**

- ❖ Rapid growth in infancy or adolescence
- ❖ Pregnancy

#### **Increased iron loss**

- ❖ Chronic blood loss
- ❖ Menses
- ❖ Blood donation
- ❖ Acute blood loss

#### **Decreased iron intake or absorption**

- ❖ Inadequate diet
- ❖ Malabsorption from disease (sprue, Crohn's disease)
- ❖ Malabsorption from surgery (post-gastrectomy)

### **Treatment**

#### **Oral iron**

Ferrous sulfate, 325 mg (65 mg elemental iron) PO tid taken between meals to maximize absorption.

GI side effects, such as constipation, cramping, diarrhea, or nausea, develop in approximately 25% of patients.

#### **Parenteral iron**

Indications for parenteral iron include poor enteral absorption, continued blood loss, or intolerance to oral iron.

RBC transfusion is indicated to increase the oxygen-carrying capacity of blood in anemic patients. Transfusion threshold (in general):

- ❖ Hemoglobin 7-8 g/dL with no cardiac risk.
- ❖ Hemoglobin 10 g/dL with a history of coronary artery disease or risk of ischemia.

## ANEMIA OF CHRONIC DISEASE AND INFLAMMATION

### **Definition**

---

- ❖ Anemia of chronic disease refers to anemia that occurs in the setting of a chronic disease state, usually one associated with elevated levels of inflammatory cytokines
- ❖ It occurs in a variety of chronic inflammatory disorders, including the following:
  1. Chronic microbial infections such as osteomyelitis, bacterial endocarditis, and lung abscess.
  2. Chronic immune disorders such as rheumatoid arthritis and regional enteritis.
  3. Neoplasms such as Hodgkin disease and carcinomas of the lung and breast.

## **MEGALOBLASTIC ANEMIAS**

### **Objectives**

The student will;

- 1) Understand the basic mechanisms underlying megaloblastic anemia
- 2) Understand the basic role of vitamin B12 and folic acid in erythropoiesis
- 3) Know the various causes leading to megaloblastic anemia
- 4) Know the clinical features of megaloblastic anemia
- 5) Understand the basic treatment options for megaloblastic anemia

### **Definition**

---

Megaloblastic anemias, a group of disorders characterized by a distinct morphologic pattern in hematopoietic cells, are commonly due to deficiency of vitamin B12 (cobalamin) or folates

### **Normal Physiology**

---

#### Absorption and Transport

- Cobalamin in food is usually in coenzyme form (as deoxyadenosylcobalamin and methylcobalamin) and bound to proteins .
- In the stomach, peptic digestion at low pH is a prerequisite for release of cobalamin from food protein.
- Once released by proteolysis, cobalamin preferentially binds with a high-affinity cobalamin-binding protein called R protein, which is secreted in salivary and gastric juice.
- These cobalamin–R protein complexes along with unbound intrinsic factor, which is produced by gastric parietal cells, pass into the second part of the duodenum, where pancreatic proteases degrade the R protein to which cobalamin is bound, thereby allowing transfer of cobalamin to intrinsic factor.

**CAUSES OF COBALAMIN DEFICIENCY SUFFICIENTLY SEVERE TO CAUSE MEGALOBLASTIC ANEMIA**

❖ <b>Nutritional</b>	Vegans
❖ <b>Malabsorption</b>	Pernicious anemia
❖ <b>Gastric causes</b>	Congenital absence of intrinsic factor or functional abnormality Total or partial gastrectomy
❖ <b>Intestinal causes</b>	Intestinal stagnant loop syndrome: jejunal diverticulosis, ileocolic fistula, anatomic blind loop, intestinal stricture, etc. Ileal resection and Crohn's disease Tropical sprue Fish tapeworm

**PERNICIOUS ANEMIA**

- ❖ Pernicious anemia (PA) may be defined as a severe lack of IF due to gastric atrophy.
- ❖ The disease occurs more commonly than by chance in close relatives and in persons with other organ-specific autoimmune diseases, e.g., thyroid diseases, vitiligo, hypoparathyroidism, and Addison's disease.
- ❖ Gastric Biopsy:

This usually shows atrophy of all layers of the body and fundus, with loss of glandular elements, an absence of parietal and chief cells and replacement by mucous cells, a mixed inflammatory cell infiltrate, and perhaps intestinal metaplasia

**Clinical features of megaloblastic anemia**

- Folate-deficient patients present with sleep deprivation, fatigue, and manifestations of depression, irritability, or forgetfulness.
- By the time vitamin B12 deficiency anemia is clinically evident, the main manifestations are usually neurologic symptoms, such as peripheral neuropathy, paresthesias, lethargy, hypotonia, and seizures.
- Important physical findings include signs of poor nutrition, pigmentation of skin creases and nail beds, or glossitis.
- *Jaundice or splenomegaly* may indicate ineffective and extramedullary hematopoiesis.
- Vitamin B12 deficiency may cause *decreased vibratory and positional sense, ataxia, paresthesias, confusion, and dementia.*
- Folic acid deficiency *does not result in neurologic disease.*

## **Treatment**

- 1) Folic acid 1 mg PO daily until the deficiency is corrected. High doses of folic acid (5 mg PO daily) may be needed in patients with malabsorption syndromes.
- 2) Vitamin B12 deficiency is corrected by administering vitamin B12. A typical schedule is 1 mg IM daily for 7 days, then weekly for 1-2 months or until normalization of the Hb occurs. Long-term therapy is 1 mg IM monthly.

## **HEMOLYTIC ANEMIAS**

### **Objectives**

The student will

- 1) Understand the basic facts about erythropoiesis
- 2) Understand the basic causes underlying mechanism and classification of various types of hemolytic anemia
- 3) Know the clinical presentation of various types of hemolytic anemia
- 4) Know the basic treatment options of various types of hemolytic anemia

### **Introduction**

- a) Normal RBCs have a life span of about 120 days. Anemias that are associated with a decreased RBC life span are termed hemolytic anemias. Shortened survival may be caused by either inherent (intracorpuscular) RBC defects, which are usually inherited, or external (extracorpuscular) factors, which are usually acquired.
- b) All are characterized by (1) an increased rate of RBC destruction; (2) a compensatory increase in erythropoiesis that results in reticulocytosis; and (3) the retention by the body of the products of RBC destruction, including iron. Because the iron is conserved and recycled readily, RBC regeneration can keep pace with the hemolysis. Consequently, these anemias are almost invariably associated with a marked erythroid hyperplasia within the marrow and an increased reticulocyte count in peripheral blood. If the anemia is severe, extramedullary hematopoiesis may develop in the spleen, liver, and lymph nodes.
- c) Destruction of RBCs may occur within the vascular compartment (intravascular hemolysis) or within the cells of the mononuclear phagocyte, or reticuloendothelial (RE), system (extravascular hemolysis).
- d) Intravascular hemolysis occurs when RBCs are subjected to mechanical trauma or damaged by a variety of biochemical or physical agents (e.g., fixation of complement, exposure to clostridial toxins, or heat). Regardless of cause, intravascular hemolysis results in hemoglobinemia, hemoglobinuria, and hemosiderinuria.

- e) Conversion of the heme pigment to bilirubin may give rise to unconjugated hyperbilirubinemia and jaundice. Massive intravascular hemolysis sometimes leads to acute tubular necrosis . Levels of serum haptoglobin, a protein that binds free Hb, are characteristically low.
- f) Extravascular hemolysis, the more common mode of RBC destruction, takes place largely within the phagocytic cells of the spleen and liver. The mononuclear phagocyte system removes erythrocytes from the circulation whenever RBCs are injured or immunologically altered.
- g) Because extreme alterations of shape are necessary for RBCs to successfully navigate the splenic sinusoids, reduced deformability makes this passage difficult and leads to splenic sequestration, followed by phagocytosis.
- h) Extravascular hemolysis is not associated with hemoglobinemia and hemoglobinuria, but it may result in jaundice and, if of long standing, in the formation of bilirubin-rich gallstones (so-called pigment stones).
- i) Because the pathways for the excretion of excess iron are limited, there is a tendency in hemolytic anemias for abnormal amounts of iron to accumulate, giving rise to systemic hemosiderosis or, in very severe cases, secondary hemochromatosis

### Classification of Hemolytic Anemias

	<i>Intracorpuseular Defects</i>	<i>Extracorpuseular Factors</i>
<b>Hereditary</b>	<ul style="list-style-type: none"> <li>• Hemoglobinopathies</li> <li>• Enzymopathies</li> <li>• Membrane-cytoskeletal defects</li> </ul>	<ul style="list-style-type: none"> <li>• Familial hemolytic uremic syndrome (HUS)</li> </ul>
<b>Acquired</b>	<ul style="list-style-type: none"> <li>• Paroxysmal nocturnal hemoglobinuria (PNH)</li> </ul>	<ul style="list-style-type: none"> <li>• Mechanical destruction (microangiopathic)</li> <li>• Toxic agents</li> <li>• Drugs</li> <li>• Infectious</li> <li>• Autoimmune</li> </ul>

## **General Clinical Features**

---

- ❖ What differentiates HA from other anemias is that the patient has signs and symptoms arising directly from hemolysis.
- ❖ At the clinical level, the main sign is jaundice; in addition, the patient may report discoloration of the urine. In many cases of HA, the spleen is enlarged because it is a preferential site of hemolysis, in some cases the liver may be enlarged as well.
- ❖ In all severe congenital forms of HA, skeletal changes may be noted due to over-activity of the bone marrow (although they are never as severe as in thalassemia).

## **Compensated Hemolysis versus HA**

Red cell destruction is a potent stimulus for erythropoiesis, which is mediated by erythropoietin (EPO) produced by the kidney. This mechanism is so effective that in many cases the increased output of red cells from the bone marrow can fully balance an increased destruction of red cells.

In such cases we say that hemolysis is compensated.

This notion is important from the diagnostic point of view, because a patient with a hemolytic condition, even an inherited one, may present without anemia.

## **INHERITED HEMOLYTIC ANEMIAS**

There are three essential components in the red cell: (1) hemoglobin, (2) the membrane-cytoskeleton complex, and (3) the metabolic machinery necessary to keep (1) and (2) in working order.

### **HEMOLYTIC ANEMIAS DUE TO ABNORMALITIES OF THE MEMBRANE-CYTOSKELETON COMPLEX**

#### ***HEREDITARY SPHEROCYTOSIS***

---

- ❖ This disorder is characterized by an inherited (intrinsic) defect in the RBC membrane that renders the erythrocytes spheroidal, less deformable, and vulnerable to splenic sequestration and destruction.

#### **Clinical Manifestations**

- a) The spectrum of clinical severity of HS is broad. Severe cases may present in infancy with severe anemia, whereas mild cases may present in young adults or even later in life.
- b) In women, HS is sometimes first diagnosed when anemia is investigated during pregnancy. The main clinical findings are jaundice, an enlarged spleen, and often gallstones.
- c) Frequently it is the finding of gallstones in a young person that triggers diagnostic investigations.

## **Treatment**

- 1) Most hematologists recommend splenectomy for children with severe hereditary spherocytosis (hemoglobin concentration, <8 g/dL; reticulocyte count, >10%) and for children with moderate disease (hemoglobin concentration, 8 to 11 g/dL; reticulocyte count, 8 to 10%) if the degree of anemia compromises physical activity.
- 2) In adults with moderate hereditary spherocytosis, additional indications for splenectomy include a degree of anemia that compromises oxygen delivery to vital organs, the development of extramedullary hematopoietic tumors, and the occurrence of bilirubinate gallstones, which could predispose to cholecystitis and biliary obstruction.
- 3) Splenectomy is generally deferred in patients with mild hereditary spherocytosis (hemoglobin concentration, >11 g/dL; reticulocyte count, <8%).
- 4) All patients undergoing splenectomy should receive polyvalent pneumococcal vaccine, preferably several weeks before the operation; children should also receive meningococcal and Haemophilus influenzae B vaccines.
- 5) All patients with hereditary spherocytosis should be given 1 mg of folate as a daily supplement (patients with moderate to severe disease may require 5 mg daily) to prevent megaloblastic crisis.

## **HEMOGLOBINOPATHIES: THE THALASSEMIAS**

### **Introduction**

- ❖ The hemoglobinopathies are a group of hereditary disorders characterized by the presence of a structurally abnormal Hb.
- ❖ Hemoglobinopathies are disorders affecting the structure, function, or production of hemoglobin. These conditions are usually inherited and range in severity from asymptomatic laboratory abnormalities to death in utero. Different forms may present as hemolytic anemia, erythrocytosis, cyanosis, or vasoocclusive stigmata.
- ❖ Hemoglobin Structure :Different hemoglobins are produced during embryonic, fetal, and adult life (Fig. 99-1). Each consists of a tetramer of globin polypeptide chains: a pair of  $\alpha$ -like chains 141 amino acids long and a pair of  $\beta$ -like chains 146 amino acids long. The major adult hemoglobin, HbA, has the structure  $2\alpha 2\beta$ . HbF ( $2\alpha 2\gamma$ ) predominates during most of gestation, and HbA<sub>2</sub> ( $2\alpha 2\delta$ ) is minor adult hemoglobin

## CLASSIFICATION OF HEMOGLOBINOPATHIES

❖ **Structural hemoglobinopathies**—hemoglobins with altered amino acid sequences that result in deranged function or altered physical or chemical properties:

- a) Abnormal hemoglobin polymerization—HbS, hemoglobin sickling
- b) Hemoglobins that oxidize readily
- c) M hemoglobins—methemoglobinemia, cyanosis

❖ **Thalassemias**—defective biosynthesis of globin chains

- a)  $\alpha$  Thalassemias
- b)  $\beta$  Thalassemias

❖ **Hereditary persistence of fetal hemoglobin**—persistence of high levels of HbF into adult life

❖ **Acquired hemoglobinopathies**

- a) Methemoglobin due to toxic exposures
- b) Sulfhemoglobin due to toxic exposures
- c) Carboxyhemoglobin

## THALASSEMIA SYNDROMES

### **Definition**

- The thalassemia syndromes are a heterogeneous group of inherited anemias characterized by defects in the synthesis of one or more globin chain subunits of the adult hemoglobin tetramer (HbA).
- Patients with  $\beta$ -thalassemia have a decrease in  $\beta$ -chain production relative to  $\alpha$ -chain production; the converse is the case in  $\alpha$ -thalassemia.
- The clinical syndromes associated with thalassemia arise from the combined effects of inadequate hemoglobin production and unbalanced accumulation of globin subunits.
- The former causes hypochromia and microcytosis; the latter leads to ineffective erythropoiesis and hemolytic anemia.

### **Clinical Manifestations**

---

- a) Splenomegaly and bone abnormalities caused by the expanded marrow are common in more severe forms of thalassemia.
- b) Massive bone marrow expansion deranges growth and development. Children develop characteristic "chipmunk" facies due to maxillary marrow hyperplasia and frontal bossing. Thinning and pathologic fracture of long bones and vertebrae may occur due to cortical invasion by erythroid elements and profound growth retardation.
- c) Hepatomegaly, signs of congestive heart failure, short stature, and hypogonadism are commonly due to transfusion-related iron overload.

### **Treatment**

---

#### Transfusion Therapy

- ❖ Packed RBCs (PRBCs): A Hb of  $>9$  g/dL improves exercise tolerance and prevents skeletal deformities and can usually be achieved with 1 unit of RBCs every 2-3 weeks or 2 units every month
- ❖ In severe forms of thalassemia, the transfusions result in tissue iron overload, which may cause congestive heart failure (CHF), hepatic dysfunction, glucose intolerance, and secondary hypogonadism. Iron chelation therapy delays or prevents these complications.
- ❖ Deferoxamine, 40 mg/kg subcutaneously (SC) or intravenously (IV) over 8-12 hours continuous infusion.

### Surgery

Splenectomy removes the primary site of extravascular hemolysis and should be considered if RBC transfusion requirements increase and exceed one and a half times the previous levels.

### Stem Cell Transplant

Stem cell transplant (SCT) should be considered in young patients with beta-thalassemia major who have an HLA-identical sibling

## **SICKLE CELL DISEASE AND ASSOCIATED HEMOGLOBINOPATHIES**

### **Definition**

---

Sickle cell disease is a group of chronic hemolytic anemias, all characterized by vasculopathy, vaso-occlusive disease, widespread acute and chronic organ damage, and a reduced lifespan.

### **Pathophysiology**

---

- a) The disease is caused by a mutation in the gene encoding the  $\beta$ -globin chain that causes the formation of sickle Hb (HbS). Substitution of valine for glutamic acid at the sixth position of the  $\beta$ -chain produces HbS.
- b) On deoxygenation, HbS molecules undergo polymerization, a process sometimes called gelation or crystallization. The change in the physical state of HbS distorts the RBCs, which assume an elongated crescentic, or sickle, shape.
- c) Sickling of RBCs is initially reversible by oxygenation; however, membrane damage occurs with each episode of sickling, and eventually the cells accumulate calcium, lose potassium and water, and become irreversibly sickled, despite adequate oxygenation.
- d) Two major consequences stem from the sickling of RBCs: First, repeated episodes of deoxygenation cause membrane damage and dehydration of RBCs, which become rigid and irreversibly sickled. These dysfunctional RBCs are recognized and removed by mononuclear phagocyte cells, producing a chronic extravascular hemolytic anemia.
- e) Second, the sickling of RBCs produces widespread microvascular obstructions and resulting ischemic tissue damage. Vaso-occlusion can be triggered and exacerbated by infection, inflammation, dehydration, and acidosis.

## Clinical Manifestations

---

- ❖ Most patients with sickle cell anemia have moderate anemia.
- ❖ Patients with the most profound hemolysis appear more likely to have stroke, pulmonary hypertension, priapism, and leg ulcers.

FEATURES OF SICKLE CELL ANEMIA
1) Painful episodes 2) Acute chest syndrome 3) Stroke 4) Osteonecrosis 5) Priapism 6) Splenic infarction and sequestration 7) Leg ulcers 8) Gallstones 9) Aplastic crisis 10) Pneumococcal disease and sepsis



## Treatment

---

### Medications

- 1) Antimicrobial prophylaxis with penicillin VK, 125 mg PO bid up to age 3 years, then 250 mg PO bid until 5 years, is effective in reducing the risk of infection
- 2) Opioids are typically used and are effectively administered by a patient-controlled analgesia pump, allowing for the patient to self-administer medication within a set limit of infusions (lockout interval) and basal rate.
- 3) Folic acid, 1 mg PO daily, should be administered to patients with sickle cell disease because of chronic hemolysis.
- 1) RBC transfusions are indicated for patients with strokes, transient ischemic attacks, acute chest syndrome, aplastic crisis, priapism that is unresponsive to supportive care, and in preparation for general anesthesia
- 2) Hydroxyurea (15-35 mg/kg PO daily) has been shown to increase levels of fetal Hb and decrease the incidence of vaso-occlusive pain episodes by approximately 50% and acute chest syndrome by approximately 70% in adults with sickle cell anemia.

HEMOLYTIC ANEMIA DUE TO ENZYME DEFECTS
--

When there is an important defect in the membrane or in the cytoskeleton, hemolysis is a direct consequence of the fact that the very structure of the red cell is abnormal.

Instead, when one of the enzymes is defective, the consequences will depend on the precise role of that enzyme in the metabolic machinery of the red cell, which, in its first

approximation, has two important functions: (1) to provide energy in the form of ATP, and (2) to prevent oxidative damage to hemoglobin and to other proteins.

## **G6PD DEFICIENCY**

- a) Glucose 6-phosphate dehydrogenase (G6PD) is a housekeeping enzyme critical in the redox metabolism of all aerobic cells.
  - b) In red cells, its role is even more critical because it is the only source of reduced nicotinamide adenine dinucleotide phosphate (NADPH), which, directly and via reduced glutathione (GSH), defends these cells against oxidative stress.
- G6PD deficiency is a prime example of an HA due to interaction between an intracorporeal and an extracorporeal cause, because in the majority of cases hemolysis is triggered by an exogenous agent

### **Clinical Manifestations**

- 1) The vast majority of people with G6PD deficiency remain clinically asymptomatic throughout their lifetime.
- 2) Acute HA can develop as a result of three types of triggers: (1) fava beans, (2) infections, and (3) drugs.
- 3) Typically, a hemolytic attack starts with malaise, weakness, and abdominal or lumbar pain. After an interval of several hours to 2–3 days, the patient develops jaundice and often dark urine, due to hemoglobinuria.

### **Drugs that Carry Risk of Clinical Hemolysis in Persons with G6PD Deficiency**

Antimalarials	Primaquine
Sulphonamides/sulphones	Sulphametoxazole
Antibacterial/antibiotics	Cotrimoxazole Nalidixic acid Nitrofurantoin
Antipyretic/analgesics	Phenazopyridine (Pyridium)

### **Diseases/Clinical Situations with Predominantly Intravascular Hemolysis**

	Onset/Time Course	Main Mechanism	Appropriate Diagnostic Procedure
<b>1) Mismatched blood transfusion</b>	Abrupt	Nearly always ABO incompatibility	Repeat cross match

<b>2) Paroxysmal nocturnal hemoglobinuria (PNH)</b>	Chronic with acute exacerbations	Complement (C)-mediated destruction of CD59(-) red cells	Flow cytometry to display a CD59(-) red cell population
<b>3) Paroxysmal cold hemoglobinuria (PCH)</b>	Acute	Immune lysis of normal red cells	Test for Donath-Landsteiner antibody
<b>4) Septicemia</b>	Very acute	Exotoxins produced by Clostridium perfringens	Blood cultures
<b>5) Microangiopathic</b>	Acute or chronic	Red cell fragmentation	Red cell morphology on blood smear
<b>6) March hemoglobinuria</b>	Abrupt	Mechanical destruction	Targeted history taking
<b>7) Favism</b>	Acute	Destruction of older fraction of G6PD-deficient red cells	G6PD assay

### **Treatment**

- ❖ Avoid offending medications.
- ❖ Provide adequate hydration to protect renal function during hemolysis.
- ❖ Conduct RBC transfusion for more severe forms.

## **AUTOIMMUNE HEMOLYTIC ANEMIAS**

### **Definition**

The immune-mediated hemolytic anemias comprise a group of disorders in which antibodies, complement, and macrophages, usually acting in concert, send the patient's red blood cells to a premature demise.

## **Pathophysiology**

---

- a) These uncommon forms of hemolytic anemia are caused by antibodies that react against normal or altered RBC membranes. Anti-RBC antibodies may arise spontaneously in autoimmune hemolytic anemias, or they may be induced to form by exogenous agents such as drugs or chemicals.
- b) Whatever the cause of antibody formation, the diagnosis of immunohemolytic anemias depends on the demonstration of anti-RBC antibodies. The method most commonly used to detect such antibodies is the Coombs antiglobulin test, which is based on the capacity of antibodies raised in animals against human immunoglobulins to agglutinate RBCs.
- c) A positive result indicates that the patient's RBCs are coated with human antibodies that can react with the antihuman immunoglobulin serum. This is called the direct Coombs test.
- d) The indirect Coombs test is used to detect antibodies in the patient's serum and involves incubating normal RBCs with the patient's serum, followed by a direct Coombs test on these incubated RBCs.

## **CLASSIFICATION OF IMMUNOHEMOLYTIC ANEMIAS**

### ***Warm Antibody Type***

- ❖ Primary (idiopathic)
- ❖ Secondary: B-cell lymphoid neoplasms (e.g., CLL/SLL), SLE, drugs (e.g.,  $\alpha$ -methyl dopa, penicillin, quinidine)

### ***Cold Antibody Type***

- ❖ Acute: Mycoplasma infection, infectious mononucleosis
- ❖ Chronic: idiopathic, B-cell lymphoid neoplasms (e.g., lymphoplasmacytic lymphoma)

## **Warm Antibody Immuno-hemolytic Anemias**

- 1) These are characterized by the presence of immunoglobulin G (IgG) antibodies, which are active at 37°C.
- 2) Many cases (more than 60%) are idiopathic (primary) and belong to the category of autoimmune diseases.
- 3) Approximately one fourth of the cases are associated with an underlying disease (e.g., systemic lupus erythematosus [SLE]) affecting the immune system or are induced by drugs.

- 4) The pathogenesis of hemolysis in most instances involves opsonization of the RBCs by the IgG antibodies and subsequent phagocytosis by splenic macrophages.

### **Cold Antibody Immuno-hemolytic Anemias**

- 1) These anemias are characterized by the presence of low-affinity immunoglobulin M (IgM) antibodies, which bind to RBC membranes at temperatures below 30°C, as may be encountered in distal body parts (e.g., hands, toes).
- 2) Fixation of complement may cause intravascular hemolysis. However, most commonly the antibody- and complement-coated cells are not lysed.
- 3) When such antibody- and complement-coated cells travel to warmer areas, the weakly bound IgM antibody is released, and the cell is left with a coating of C3b. The cells are phagocytosed by the mononuclear phagocyte system, especially Kupffer cells; hence, the hemolysis is extravascular.

### **Clinical Features**

---

- 1) The onset of AIHA is very often abrupt and can be dramatic.
- 2) The hemoglobin level can drop, within days, to as low as 4 g/dL; the massive red cell removal will produce jaundice, and often the spleen will be enlarged. When this triad is present, the suspicion of AIHA must be high.
- 3) When hemolysis is (in part) intravascular, the telltale sign will be hemoglobinuria, which the patient may report or for which the physician must test.
- 4) Severe hemolysis may be associated with fever, chest pain, syncope, CHF, and hemo- globinuria.
- 5) Episodic cold-induced intravascular hemolysis and vaso-occlusive events resulting in cyanosis of the ears, nose, fingers, and toes occur specifically in cold agglutinin disease.

### **Treatment**

---

- ❖ Both warm and cold AIHA therapy should be directed at identifying and treating any underlying cause
  - ❖ Warm AIHA
- 1) Glucocorticoids, such as prednisone 1 mg/kg. If patients are sensitive to glucocorticoids, response is typically seen in 7-10 days. When hemolysis has abated, glucocorticoids can be tapered over 2-3 months. Rapid steroid tapers can result in relapse.
  - 2) IVIG is less effective than in ITP, with a response rate of about 40%.
  - 3) Splenectomy should be considered for steroid-resistant AIHA.

4) Rituximab, 375 mg/m<sup>2</sup> IV weekly for four doses, has shown efficacy in small case series

❖ Idiopathic cold AIHA

- 1) Glucocorticoids and splenectomy are not efficacious.
- 2) Rituximab has been demonstrated to be effective in a case reports
- 3) In severe cases, plasma exchange may be used to remove offending IgM antibody (which is 80% intravascular) to control the disease while other therapies are administered.

### **Clinical Pathology of Microcytic, Macrocytic And Hemolytic Anaemia**

Normal adult hematological values RBC count: male: 4.5-5.5 million /cmm , female: 3.8-4.8 million /cmm, Hemoglobin level: male:13-17 gm/dl ,female: 12-15 gm/dl, Packed cell volume (PCV or HCT) male: 40-50 % ,female: 36-46% ,MCV:80-100 , MCH :27-32 ,MCHC: 32-35 Reticulocyte count :0.5-2.5%, Platelet count: 150,000-400,000/cmm. Total leucocytes count: 4000-10000/cmm .

Anemia is defined as a reduction in hemoglobin concentration (Hb) below the normal range for the age and sex of the patient. Reduction of Hb is usually accompanied by a fall in RBCs count and hematocrit (HCT or PCV). However, RBCs count may be normal in some anemic patients.

Hypochromic microcytic anemia is characterized by low MCH (hypochromic) and low MCV (microcytic). It is due the following causes: Iron deficiency anemia, Sideroblastic anemia, chronic disorders and thalassemia (alpha or B)

**1-Iron deficiency anemia(IDA):** Iron is distributed in the body in several forms: Hemoglobin iron: 60-70% of total body iron ; Plasma iron: iron circulates in plasma bound to protein called transferrin and storage iron as ferritin There are three main causes of iron deficiency: Increased physiological demand :as in women during their reproductive life (menstruation and pregnancy) ; Inadequate intake: This may result from either nutritional deficiency or mal absorption; and chronic blood loss as in menorrhagia, oesophageal varices ,peptic ulcer, aspirin ingestion (or other anti -inflammatory drugs), carcinoma of stomach, colon or rectum.

Blood picture: Hemoglobin is reduced usually of mild or moderate severity; MCV, MCH, MCHC are reduced. RBCs: are hypochromic and microcytic. Reticulocyte count: is low (↑ after treatment or in bleeding) . WBCs and platelets are usually normal. There are decreased serum iron, increased TIBC (total iron binding capacity) and decreased transferrin iron saturation. Serum ferritin is decreased (early finding). Soluble transferrin receptors are increased. Serum hepcidin level is decreased. Bone marrow (BM) shows absence of iron stores

**2- Sideroblastic anemia:** is characterized by the presence of many pathological ring sideroblasts in the bone marrow (15% or more). It is due to defect in heme synthesis pathway, with a lack of heme in which iron is to be incorporated. It is either hereditary or acquired.

Blood picture: The main feature is dimorphic blood picture with the presence of normocytic normochromic cells and hypochromic microcytic cells. Bone marrow: shows excess ring sideroblasts(>15%). Increased serum iron, increased serum ferritin and TIBC is normal

**3-Anemia of chronic disorders:** One of the most common anemias occur in patients with a variety of inflammatory and malignant disorders. It is due to chronic inflammatory disease as chronic Infections or noninfectious: as in rheumatoid arthritis, systemic lupus erythematosus (SLE) , or malignant diseases. Anemia is due to Impaired flow or release of iron from macrophages to erythroblasts. It may be due to increase production of certain substance (hepcidin) by the liver in response to inflammation, which inhibits macrophage release of iron. Hepcidin also inhibits iron absorption from the duodenum

Blood picture: Normocytic normochromic or mild hypochromic microcytic anemia. The anemia is mild (Hb is rarely <9 gm/dl). Both Serum iron and TIBC are reduced. Ferritin is Normal or increased. BM storage iron (macrophages) is present, but erythroblasts iron is absent.

**4-Thalassaemia:** hereditary disorders characterized by reduced rate of production of normal hemoglobin due to decreased synthesis of globin chains. In B-thalassemia, there is a defect in production of B chain which lead to reduction of HbA ( $\alpha_2\text{B}_2$ ) and increase production of HbA<sub>2</sub>( $\alpha_2\text{Delta}_2$ ) and HbF ( $\alpha_2\text{Gamma}_2$ ). In alpha( $\alpha$ ) thalassemia there is a defect in production in  $\alpha$  chain and other types of Hb are produced as Hb H(B<sub>4</sub>)

B thalassemia trait: It is the heterozygous state of thalassemia gene. It has the following characteristics: Mild anemia (Hb is rarely <10 gm/dl); Very low MCV and MCH; RBCs count is usually normal or even high. Serum iron, TIBC, and ferritin are often normal. Hemoglobin electrophoresis reveals  $\uparrow$ Hb A<sub>2</sub>.

B thalassemia major: It is the homozygous state of thalassemia gene. It is characterized by: severe hypochromic microcytic anemia. RBCs showed hypochromia, microcytes, target cells and many normoblasts (nucleated RBCs). There are evidences of hemolysis as  $\uparrow$ indirect bilirubin, and reticulocytosis. Serum iron and ferritin is high, TIBC is usually normal or decreased in severe cases and % iron saturation is increased. Hemoglobin electrophoresis shows increased Hb F .

Macrocytic megaloblastic anemia: It is a group of anemia in which megaloblasts are found in the bone marrow. The megaloblasts are abnormal erythroblasts with a

characteristic abnormality (maturation of the nucleus being delayed relative to that of cytoplasm). This defect is due to impaired DNA synthesis as a result of deficiency of vitamin B12 or folate. Vitamin B12 deficiency is due to decreased intake or Impaired absorption due to intestinal or gastric causes. Intestinal causes are due to malabsorption or surgical removal of ileum. Gastric causes are due to pernicious anemia (failure of secretion of intrinsic factor) or after gastrectomy. The fundamental defect of pernicious anemia is lack of intrinsic factor (IF) due to atrophy of gastric mucosa. In the absence of IF, vitamin B12 is not absorbed resulting in vitamin B12 deficiency. Many types of auto antibodies are found in pernicious anemia as parietal cell antibodies and intrinsic factor antibodies. Folic acid deficiency is due to Inadequate intake; intestinal malabsorption; Increased demand: as in pregnancy, and taking folate antagonists as methotrexate (used in malignancy)

Biochemical function of B12 and folate: Vitamin B12 is responsible for two critical enzymatic reactions that promote cell metabolism. B12 promotes the conversion of methyl malonyl CoA (a form of methyl malonic acid) to succinyl Coenzyme A, and with folic acid, aids in converting homocysteine to methionine

Blood picture: The anemia is macrocytic and MCV is  $>100$  and may reach as high as 120-140. Moderate leucopenia may be found (due to premature destruction in BM) with the presence of hyper segmented neutrophils (six lobed or more). Mild symptomless thrombocytopenia (due to premature destruction in BM) may be found. Reticulocytic count is low. Serum unconjugated bilirubin and LDH are increased due to excessive destruction of RBCs from ineffective erythropoiesis in bone marrow. Serum B12 is decreased in megaloblastic anemia caused by B12 $\downarrow$ . Serum and red cell folate are both decreased in megaloblastic anemia caused by folate deficiency. Serum homocysteine and methyl malonic acid are helpful confirmatory tests for B12 and folate deficiencies specially in early cases with borderline results of serum B12 or serum folate. The measurement of methylmalonic acid in the blood or urine serves as a sensitive and early indicator of vitamin B12 deficiency. Both methylmalonic acid and homocysteine are increased in B12 deficiency. Homocysteine but not methylmalonic acid is increased in folate deficiency.

Bone marrow is hypercellular with erythroid hyperplasia and there are megaloblastic changes in all stages of red cell development.

Causes of non-megaloblastic macrocytic anemia (normoblastic bone marrow): Liver diseases, Aplastic anemia, Myxedema, BM infiltrations, Alcoholism and Post hemorrhagic anemia.

Hemolytic anemia: Hemolytic anemia (HA) is defined as anemia resulting from an increase in the rate of red cell destruction. The premature destruction of RBCs may result from intrinsic defect of RBCs or extrinsic defect. Intrinsic defects may be

membrane defect (hereditary spherocytosis), hemoglobin defect (as sickle cell disorders and thalassemia) or enzyme defect as G6PD deficiency. Extrinsic defects are due to autoimmune hemolytic anemia, incompatible blood transfusion drugs, infection (as malaria), and others.

Laboratory findings of hemolytic anemia: increased serum bilirubin (unconjugated bilirubin), increased urine urobilinogen, increased fecal stercobilinogen, increased serum LDH enzyme and decrease haptoglobin. The latter is formed in liver. Haptoglobin combines with hemoglobin to form a complex which is removed by reticuloendothelial cells. Reticulocyte count is high, and BM shows erythroid hyperplasia.

Intra and extra vascular hemolysis: Hemolysis is either due to excessive removal of RBCs by cells of reticuloendothelial system (extravascular hemolysis) or RBCs may be broken in the circulation (intravascular hemolysis). In intravascular hemolysis, free Hb is released and increased in plasma (hemoglobinemia) which rapidly saturate plasma haptoglobin and the excess free Hb is filtered by the kidney and appear in urine (hemoglobinuria). Iron is released and stored in renal tubular cells as hemosiderin which is excreted in urine (hemosiderinuria). Causes of intravascular hemolysis include Incompatible blood transfusion, Infection (as malaria), and G6PD deficiency.

**Glucose -6 phosphate dehydrogenase (G6PD) deficiency:** G6PD functions to reduced glutathione which is very important to protect RBCs from oxidative damage. It is sex linked inherited, in whom X chromosome carries the mutant gene. It affects males predominantly Female are usually carrier and not affected except in homozygous state. The patient presents with acute hemolytic anemia in response to oxidative stress by Drugs as sulphonamides, Quinolones, antimalarial drugs and others; or Fava bean (Favism) or Infection.

Blood picture: Between crises the blood count is normal. During crises: there is moderate to severe anemia. RBCs shows Heinz bodies (oxidized denatured Hb) in the Reticulocytic stain preparation. Diagnosis Is established by measurement of G6PD enzyme in RBCs. The level is low or even absent. However, during crises higher values of enzyme may occur because Its level is high in younger cells. The assay should be repeated after 2 months from the attack.

**Sickle cell disorders:** RBCs contain abnormal Hb called Hb S. The latter differs from Hb A in the substitution of valine for glutamic acid in the six position of beta chain. In the deoxygenated state, the solubility of Hb S is very low, and it polymerize into long fibers. These changes cause RBCs to assume a sickle shape and become easily destroyed with hemolytic crises. Sickling of red cells in circulation will Block small blood vessels causing ischemia and infarction.

**Blood picture of sickle cell anemia (homozygous state):** Moderate to severe normocytic normochromic anemia. Sickle cells are usually found in blood film. There

are evidences of hemolysis ( $\uparrow$  indirect bilirubin, gall stones,  $\uparrow$ reticulocytes,  $\downarrow$  haptoglobin,..) . WBCs may show neutrophil leukocytosis due to infection. Platelet is normal or slightly increased. Osmotic fragility is decreased. Hemoglobin electrophoresis shows Hb S mainly (75-95%) and no Hb A is detected. The amount of Hb F varies from 5-20%. Larger amount of Hb F is associated with mild disorder (HbF protect red cell from sickling)

**Sickle cell trait:** It is the heterozygous state of HbS gene. It is a benign condition with no anemia and normal red cells on blood film. Hematuria is a most common symptom (due to minor infarction of renal papillae). It may be liable to some complications only in cases with hypoxia as in high altitudes, anesthesia, pregnancy. Hb electrophoresis shows Hb A is about 60-70%, Hb S 30-40%, Hb A2 and Hb F are normal

**Alpha thalassemia:** These are usually caused by alpha gene deletions. There are normally four copies of alpha globin gene, two in each chromosome number 16. The genetic deletion include:

1- Loss of 4 genes: this will completely suppress alpha chain synthesis which is essential for fetal life as well as adult. This is incompatible with life and lead to death in utero (hydrops fetalis)

2- Three gene deletion: It leads to moderate hypochromic microcytic anemia with splenomegaly. This known as Hb H disease. The Hb H(4Beta) can be detected by electrophoresis or in reticulocyte preparation using supravital stain (deep blue deposit as golf ball)

3- Loss of one or two genes: It leads to alpha thalassemia trait (silent carrier). It is usually not associated with anemia. Hb electrophoresis may reveal 5-6% Hb Barts (4 gamma) in newborn period of affected infants, but in adult it is normal

### **Hereditary spherocytosis (HS):**

Red blood cell membrane composed of a lipid bilayer and integral membrane proteins. These proteins include spectrin, ankyrin, band 3, glycophorin and others. In HS the membrane defect is mostly due to defect of one or more of the previous proteins. Lack of these proteins produces membrane instability that forces the cell to become spherical. The spherocytes are more rigid than normal cells and are unable to pass rapidly through the spleen, where they die prematurely by the phagocytes in spleen (slightly enlarged). HS is inherited as an autosomal dominant trait.

Blood picture: Normocytic normochromic anemia varies from mild to severe. MCHC is increased (fully hemoglobinized small cells). Blood film reveals microspherocytes which shows loss of central pallor. There are evidences of hemolysis ( $\uparrow$ indirect bilirubin,  $\uparrow$ LDH ,reticulocytosis,..) . Coombs test is negative. This test is positive in cases of acquired spherocytosis as in autoimmune hemolytic anemia. Osmotic fragility is increased.

Osmotic fragility test lacks both sensitivity and specificity. It may be normal in mild cases and also the test does not differentiate between hereditary and acquired spherocytosis. Flow cytometry with Eosin-5-maleimide (EMA) dye binding detects the membrane defect. EMA is a fluorescent dye that binds to membrane proteins in the erythrocyte membrane. The mean fluorescence of EMA-stained erythrocytes is decreased in hereditary spherocytosis compared with healthy control. This test is more sensitive and specific than osmotic fragility.

**Aplastic anemia:** it is a disorder characterized by the occurrence of anemia, leucopenia and thrombocytopenia, resulting from aplasia of bone marrow. Causes of aplastic anemia are either primary or secondary. Primary aplastic anemia: may be idiopathic. Secondary aplastic anemia is caused by the toxic action of chemicals, drugs, ionizing radiation, or infection

Blood picture: Normocytic or slightly macrocytic anemia. The degree of anemia depends on the severity of marrow depression. Hemoglobin values varies from 12 to 3 gm/dl. Total WBCs is reduced. Platelet count is reduced. Reticulocytic count is usually low. ESR is almost high. BM shows hypoplasia with loss of haemopoietic tissue and replacement by fat which comprises over 75% of marrow

Differential diagnosis of aplastic anemia: Aplastic anemia must be differentiated from other causes of pancytopenia. The main feature of aplastic anemia is pancytopenia with high ESR and absence of immature WBCs and RBCs. Also, liver, spleen and lymph node enlargement are usually absent. (Except the draining lymph nodes of infective lesion)

Pancytopenia: The term pancytopenia is used to describe the peripheral blood picture when all the three elements of the blood are reduced i.e combination of anemia, leucopenia and thrombocytopenia .Causes of pancytopenia include aplastic anemia, sub leukemic leukemia, hypersplenism, BM infiltrations: (as in secondary carcinomas, malignant lymphoma, ..) and megaloblastic anemia.

Hemostasis: Normal blood is flowing and not clotting. In Injury blood is clotting and not flowing. Coagulation cascades include conversion of Pro-Factors to Activated Factors (through intrinsic ,extrinsic and common pathways), resulting in the conversion of prothrombin to thrombin. Thrombin converts Fibrinogen to Fibrin.

Vitamin K dependent factors: These are factor II, VII, IX , X, Protein C and S. Protein C is vitamin K–dependent glycoprotein synthesized in the liver. It exerts its anticoagulant activity primarily through inactivation of coagulation factors Va and VIIa, which are required for factor X activation and thrombin generation. The catalytic activity of Protein C is greatly enhanced by the protein S. Congenital protein C deficiency is associated with an elevated risk of venous thromboembolism as deep venous thrombosis and pulmonary embolism

## **Laboratory Evaluation of hemostatic function:**

I- Screening tests: These tests are done first before proceeding to more specific tests

1- Bleeding time (BT) it is the time that is taken for bleeding to cease from small superficial wound under standardized conditions. The bleeding time is mainly affected by platelet count, platelet function and vessel wall. However, bleeding time has low sensitivity. Prolonged BT is found in Thrombocytopenia, Platelet function defect and Vascular wall abnormalities.

2- Platelet count: Thrombocytopenia is found if count is  $<150,000/\text{cmm}$

3- Prothrombin time (PT) : PT tests the efficiency of the extrinsic and common pathway. Normal range: 11-14 seconds. Causes of prolonged PT include oral anticoagulant therapy, Liver disease, Vitamin K deficiency, DIC, and Deficiency of factors of extrinsic (VII) or common pathways ( I ,II,V,X).

4- Activated Partial thromboplastin time (PTT): PTT indicates the efficiency of intrinsic and common pathway. Normal range: 26-40 seconds. Causes of prolonged PTT include deficiency of coagulation factors involved in intrinsic (XII, XI,X,VIII) and common pathway (I,II,V,X), Liver disease, DIC and Administration of heparin.

Prolonged PT with normal PTT: extrinsic pathway abnormalities. Prolonged PTT with normal PT: Intrinsic pathway abnormality. Prolonged PT and PTT: common pathway abnormality.

5- Clotting time (CT): The time taken till the blood is clotted in tube. Normal range: 4-11 minutes. Clotting time test the intrinsic and common pathway, but it is less sensitive than PTT. Mild cases with intrinsic pathway defect may have normal clotting time, but PTT is prolonged

II- specific tests

1-Platelet function: platelet adhesion or aggregation: with aggregating agents as ristocetin,..

2- Coagulation factor assay: measure the activity of individual coagulation factor eg: F VIII assay.

3- Test for fibrin/fibrinogen degradation products (FDP) and D dimer.

**Inherited coagulation disorders:** as hemophilia A and B and Von Willebrand disease

**HEMOPHILIA A:** It is sex- linked disease due to deficiency of F VIII. It affects males and the females are usually carriers. May presents in infant with profuse hemorrhage

after circumcision or develop joint hematoma (hemarthrosis) or soft tissue hematoma. Other hemorrhagic manifestations are also found.

Laboratory findings of hemophilia A: bleeding time is normal, PTT is prolonged, PT is normal. Clotting time is prolonged in severe cases ( it is less sensitive than PTT and may be normal in mild cases).Platelet count is normal and F VIII assay show decreased activity

**Hemophilia B (Christmas disease):** It is a sex-linked disease due to deficiency of F IX (Christmas factor). Clinical picture is similar to hemophilia A. Laboratory findings: as hemophilia A Except that F IX shows decreased activity while F VIII is normal.

**Von Willebrand's disease (VWD):** it is the most common inherited bleeding disorder. The inheritance is autosomal dominant. In VWD there is quantitative deficiency or abnormal function of VWF. This protein has two roles: First it acts as an essential factor for platelet adhesion to damaged endothelium. Second it acts as a carrier for F VIII protecting it from premature destruction. Bleeding is usually common from mucous membrane (epistaxis, menorrhagia). Women are worse affected than men.

Laboratory findings of VWD: Bleeding time is prolonged due to defective platelet adhesion (however bleeding time may not be sensitive). PTT is prolonged due to decrease of F VIII. Clotting time may be prolonged but is less sensitive than PTT. Platelet count is usually normal in most cases. PT is normal. Factor VIII: may be moderately reduced. Total von Willebrand factor (VWF) antigen is reduced. Platelet aggregation is defective with ristocetin because ristocetin aggregation requires vWF, which is deficient in patient plasma.

Acquired coagulation disorders are due to deficiency of vitamin K dependent factors as in obstructive jaundice, mal absorption of vitamin K or oral anticoagulant therapy. Also found in Liver disease, DIC, heparin therapy and Inhibition of coagulation (as antibodies against F VIII)

**Disseminated Intravascular Coagulation (DIC):** DIC is a syndrome in which widespread intravascular coagulation is induced by procoagulants. DIC may cause tissue ischemia from occlusive thrombi as well as bleeding from both the consumption of platelets and coagulation factors. (Particularly fibrinogen and others). Causes of DIC include Infection (gram negative bacteria); Malignancy (promyelocytic leukemia); obstetric complications (pre-eclampsia, amniotic fluid embolism, septic abortion and intrauterine fetal death); wide spread tissue damage (following cardiac or lung surgery and release of thromboplastin from lung tissue); Liver disease and incompatible blood transfusion

Laboratory findings of DIC: Bleeding time is prolonged, Platelet count is low, PT is prolonged, PTT is prolonged, CT is prolonged, Fibrinogen level is reduced, FDPs and D

dimer are increased. Some investigators found that FDP measurement was sensitive but not specific. D-dimer measurement is more specific. D dimer is used as a confirmatory test for the nonspecific FDP .

**Thrombocytopenia:** Thrombocytopenia is defined as a platelet count less than 150,000/cmm. Bleeding time is usually prolonged, but PT, PTT and CT are normal. Causes of thrombocytopenia is either Idiopathic (ITP) or Secondary due to either reduced production (as drug induced or aplastic anemia); or increased destruction as in systemic lupus erythematosus, DIC, hypersplenism, thrombotic thrombocytopenic purpura and hemolytic uremic syndrome.

**Idiopathic thrombocytopenic purpura (ITP):** ITP is an acquired disease defined as isolated thrombocytopenia with no clinically apparent associated conditions or other causes of thrombocytopenia. In ITP antiplatelet antibodies are formed leading to peripheral platelet destruction. ITP occurs in both children and adults. Onset is gradual with petechial hemorrhage and purpura occur spontaneously or after mild trauma.

Laboratory findings of ITP: Bleeding time is prolonged; Platelet count is decreased. Bone marrow shows increased number of immature megakaryocytes. Anemia is absent unless there is iron deficiency due to chronic blood loss. Total leucocytic count is normal but may be increased during active bleeding. PT, PTT and CT are normal.

**Thrombotic thrombocytopenic purpura (TTP):** Platelets bind to abnormal large vWF multimers These platelet-vWF complexes form small blood clots which circulate in the blood vessels and cause shearing of red blood cells, resulting in their rupture and formation of schistocytes (microangiopathic hemolytic anemia MAHI) .The majority of cases were shown to be caused by deficiency or inhibition of the enzyme metalloprotease (ADAMTS13 ) by antibodies. ADAMTS13 degrades vWF and deficiency of this enzyme will lead to large vWF multimers which increase platelet adhesion and platelet thrombosis.

Clinical and laboratory findings of TTP: There is severe thrombocytopenia. Anemia is present with schistocytes RBCs (MAHA) and evidence of hemolysis are found (elevated reticulocyte count, elevated serum LDH and bilirubin, reduced haptoglobin,). The patient suffers from fever and neurological abnormalities (confusion, seizures, visual disturbances headaches,) . Mild to moderate renal affection is found. ADAMTS13 activity is severely reduced. Coagulation tests (PT, PTT, CT) are normal (in contrast to DIC)

**Hemolytic uremic syndrome (HUS):** Many cases are associated with E coli infection (O157 verotoxin strain). It often happens from eating contaminated undercooked meat. The bacterial toxins lead to endothelial and glomerular damage with thrombi formation in blood vessels. Clinical and laboratory findings of HUS: There is microangiopathic hemolytic anemia with red cell fragments (schistocytes) and evidences

of hemolysis (elevated reticulocyte count, elevated serum LDH and bilirubin, reduced haptoglobin,). Moderate thrombocytopenia is found. There is severe renal affection and renal failure is common. History of diarrhea or bloody diarrhea is usually present. Coagulation tests (PT, PTT, CT) are normal. ADAMTS13 activity is normal.

## **APLASTIC ANEMIA, MYELOYDYSPLASIA, AND RELATED BONE MARROW FAILURE SYNDROMES**

### **Introduction**

---

- ❖ The hypoproliferative anemias are normochromic, normocytic or macrocytic and are characterized by a low reticulocyte count.
- ❖ Deficient production of RBCs occurs with marrow damage and dysfunction, which may be secondary to infection, inflammation, and cancer. Anemia in these disorders is often not a solitary or even the major hematologic finding. More frequent in bone marrow failure is pancytopenia: anemia, leukopenia, and thrombocytopenia.
- ❖ Hematopoietic failure syndromes are classified by dominant morphologic features of the bone marrow.

### **DIFFERENTIAL DIAGNOSIS OF PANCYTOPENIA**

#### **PANCYTOPENIA WITH HYPOCELLULAR BONE MARROW**

##### ***ACQUIRED APLASTIC ANEMIA***

- ❖ Drugs: antimetabolites, antimetabolic agents, chloramphenicol, phenylbutazone, sulfonamides
- ❖ Radiation
- ❖ Chemicals: benzene, solvents, insecticides
- ❖ Viruses: non-A, non-B, non-C hepatitis, Epstein-Barr virus

##### ***HEREDITARY***

- ❖ Fanconi anemia

#### **PANCYTOPENIA WITH CELLULAR BONE MARROW**

##### ***PRIMARY BONE MARROW DISEASES***

- ❖ Myelodysplasia
- ❖ Paroxysmal nocturnal hemoglobinuria
- ❖ Myelofibrosis
- ❖ Myelophthisis

##### ***SECONDARY TO SYSTEMIC DISEASES***

- ❖ Systemic lupus erythematosus
- ❖ B12, folate deficiency
- ❖ Overwhelming infection
- ❖ Alcohol
- ❖ Sarcoidosis

## MYELOPHTHISIC ANEMIA

- ❖ This form of marrow failure is caused by extensive replacement of the marrow by tumors or other lesions.
- ❖ It is most commonly associated with metastatic cancer arising from a primary lesion in the breast, lung, prostate, or thyroid.
- ❖ Multiple myeloma, lymphomas, leukemias, advanced tuberculosis, lipid storage disorders, and osteosclerosis are less commonly implicated.

### Clinical Manifestations

- 1) The most common initial symptoms of aplastic anemia are caused by anemia and thrombocytopenia: progressive weakness, fatigue, headaches, dyspnea on exertion, petechia, ecchymoses, epistaxis, metrorrhagia, and gum bleeding.
- 2) Even when the neutropenia is very severe, infection is rarely an initial symptom.
- 3) The most frequent physical findings are cutaneous and conjunctival pallor and hemorrhages (petechiae, ecchymoses, and gum bleeding).
- 4) Hepatosplenomegaly and lymphadenopathy are notably absent.

### Determination of Severity

Aplastic anemia can be categorized as moderate, severe, or very severe based on the degree of pancytopenia. Severe aplastic anemia is defined by two or more of the following criteria: neutrophils less than 500/mL, platelets less than 20,000/mL, and reticulocytes less than 20,000/mL

### Treatment

- 1) If a specific cause is suspected, withdrawal of the etiologic agent is the most direct approach to treatment. Discontinuation of the suspected drug, thymectomy in patients with thymoma.
- 2) Once the diagnosis of aplastic anemia is established, family HLA typing should be performed as soon as possible, particularly in younger patients (<50 years) because these individuals are most likely to benefit from stem cell transplantation from a histocompatible sibling.
- 3) Immunosuppression has a low early mortality rate (<10%), but it is not curative and carries a 30 to 50% risk for relapse and a 20 to 30% probability of development of a myelodysplastic syndrome or PNH.
- 4) Antithymocyte globulin ,ATG (40 mg/kg/day for 4 days) alone or in combination with cyclosporine (10 mg/kg/day divided into two doses, with dose adjustments as needed to maintain levels of 200 to 400 µg/mL for 3 to 6

months and then tapered over a period of 3 months) is the treatment of choice for aplastic patients who lack a histocompatible sibling or are older than 40 years.

- 5) Response to immunosuppressive therapy is slow and progressive and may not be detected until 12 weeks after administration.

### **NEOPLASTIC PROLIFERATIONS OF WHITE CELLS**

Tumors represent the most important of the white cell disorders. They can be divided into three broad categories based on the origin of the tumor cells:

***Lymphoid neoplasms***, which include non-Hodgkin lymphomas (NHLs), Hodgkin lymphomas, lymphocytic leukemias, and plasma cell dyscrasias and related disorders

***Myeloid neoplasms*** arise from stem cells that normally give rise to the formed elements of the blood: granulocytes, RBCs, and platelets. The myeloid neoplasms fall into three fairly distinct subcategories: *acute myelogenous leukemias*, in which immature progenitor cells accumulate in the bone marrow; *chronic myeloproliferative disorders*, in which inappropriately increased production of formed blood elements leads to elevated blood cell counts; and *myelodysplastic syndromes*, which are characteristically associated with ineffective hematopoiesis and cytopenias

***Histiocytic neoplasms*** represent proliferative lesions of histiocytes. Of special interest are a spectrum of proliferations comprising Langerhans cells (the Langerhans cell histiocytoses).

### **LYMPHOID NEOPLASMS**

- ❖ The lymphoid neoplasms encompass a group of entities that vary widely in terms of their clinical presentation and behavior, thus presenting challenges to students and clinicians alike.
- ❖ Some of these neoplasms characteristically present as leukemias, arising in the bone marrow and circulating in the peripheral blood. Others, the lymphomas, typically appear as tumor masses within either lymph nodes or other organs.
- ❖ Two groups of lymphomas are recognized: Hodgkin lymphoma and non-Hodgkin lymphomas. Although both arise in the lymphoid tissue, Hodgkin lymphoma is set apart by the presence in the lesions of the distinctive neoplastic Reed-Sternberg giant cells.

### **NON-HODGKIN'S LYMPHOMAS**

Lymphomas are solid tumors of the immune system.

#### **Clinical Manifestations**

---

- a) The most common presentation of non-Hodgkin's lymphoma is *lymphadenopathy*.

- b) In general, lymph nodes containing lymphoma are *firm, nontender*, and not associated with a regional infection.
- c) In other patients, lymphadenopathy occurring in sites such as the mediastinum or retroperitoneum causes *symptoms that bring the patient to the physician*. Chest pain, cough, superior vena cava syndrome, abdominal pain, back pain, spinal cord compression, and symptoms of renal insufficiency associated with ureteral compression are characteristic.
- d) Non-Hodgkin's lymphomas are often associated with *systemic symptoms* that may lead to the diagnosis. The most obvious symptoms are fevers, night sweats, and unexplained weight loss.
- e) Non-Hodgkin's lymphomas can involve essentially any organ in the body, and *malfunction of that organ* can cause symptoms that lead to the diagnosis. Examples include neurologic symptoms with primary brain lymphoma, shortness of breath with MALT lymphomas in the lung, epigastric pain and vomiting with gastric MALT or diffuse large B-cell lymphomas, bowel obstruction with small bowel lymphomas, and skin lesions with cutaneous lymphomas.
- f) Non-Hodgkin's lymphomas can also manifest with *a variety of immunologic abnormalities*. For example, autoimmune hemolytic anemia, and immune thrombocytopenia

## **Diagnosis**

---

### TYPICAL EVALUATION OF A PATIENT NEWLY DIAGNOSED WITH NON-HODGKIN'S LYMPHOMA

❖ <b>Careful history and physical examination</b>
❖ <b>Biopsy to establish diagnosis</b>
❖ <b>Laboratory evaluation</b> Complete blood count Chemistry screen including lactate dehydrogenase and $\beta$ 2-microglobulin levels
❖ <b>Imaging studies</b> Chest radiograph Computed tomographic scan of chest, abdomen, and pelvis
❖ <b>Further biopsies</b> Bone marrow Any other suspicious site if the results of the biopsy would change therapy

## **Staging**

After diagnosis, a meticulous staging evaluation is necessary to estimate prognosis and to determine therapy. Staging requires a careful history and physical examination; a

complete blood count; renal and hepatic function tests; a serum lactate dehydrogenase (LDH) level; computed tomographic (CT) scans of the chest, abdomen, and pelvis; and a bone marrow biopsy

### **Treatment**

---

Radiotherapy is frequently used alone or in combination with chemotherapy for localized disease and is sometimes used after chemotherapy to consolidate treatment of bulky disease. Radiation therapy is also used as palliative therapy to treat symptomatic sites of relapse.

## **HODGKIN'S LYMPHOMA**

---

### **Definition**

---

Hodgkin's lymphoma, formerly called Hodgkin's disease, is one of the B-cell lymphomas. It has a characteristic neoplastic cell, the Reed-Sternberg cell, a distinct natural history, and most importantly, an excellent response to treatment, with the large majority of patients being cured.

### **Clinical Manifestations**

---

- 1) Hodgkin's lymphoma is usually manifested as lymphadenopathy, typically in the cervical, axillary, or mediastinal areas, and only about 10% of the time as nodal disease below the diaphragm.
- 2) Approximately 25% of patients with Hodgkin's lymphoma have constitutional symptoms. Significant weight loss (>10% of baseline), night sweats, or persistent fever, usually signal widespread or locally extensive disease and imply a need for systemic treatment.
- 3) Generalized pruritus, occasionally severe, can antedate the diagnosis of Hodgkin's lymphoma by up to several years.

### **Diagnosis**

---

- ❖ The diagnosis of Hodgkin's lymphoma is based on recognition of Reed-Sternberg cells or Hodgkin's cells in an appropriate cellular background in tissue sections from a lymph node or extralymphatic organ, such as bone marrow, lung, or bone.
- ❖ Fine-needle aspiration biopsy is not adequate for the diagnosis of Hodgkin's lymphoma. Open biopsy and standard histochemical staining are required to establish the diagnosis unequivocally and to determine the histologic subtype.

## **World health organization classification of Hodgkin's lymphoma subtypes**

- 1) Nodular sclerosis
- 2) Lymphocyte rich
- 3) Mixed cellularity
- 4) Lymphocyte depleted

### **Treatment**

---

- 1) Treatment is based on the presenting stage of the disease; the cell type is relatively unimportant in the natural history and prognosis.
- 2) Initial evaluation includes a CT scan of the chest, abdomen, and pelvis, and bilateral bone marrow biopsies to determine the clinical stage of the disease.
- 3) Exploratory laparotomy with splenectomy and liver biopsy is performed only if the findings will change the disease stage and treatment.
- 4) Stages I and IIA are treated with radiation therapy or a combination of chemotherapy and radiation.
- 5) Stage IIIA disease can be treated either by radiation therapy or chemotherapy, whereas all stage IV patients should receive combination chemotherapy.

## **LYMPHOMA**

- Lymphoma is a malignant neoplasm derived from lymphocytes.
- The lymphatic system is a network of tissues, vessels and organs that work together to move a colorless, watery fluid called lymph back into your circulatory system (your bloodstream).
- Primary lymphoid organs: These organs include the bone marrow and the thymus. They create special immune system cells called lymphocytes.
- Secondary lymphoid organs include lymph nodes, spleen, Peyer's patches, and mucosal tissues such as the nasal-associated lymphoid tissue, adenoids, and tonsils.
- Tertiary lymphoid organs are found at sites of chronic inflammation in autoimmune diseases such as systemic lupus erythematosus and rheumatoid arthritis. These organized accumulations of T and B cells resemble secondary lymphoid organs and generate autoreactive effector cells.

### **Types & Cell of Origin of Lymphoma**

#### **1. Hodgkin's Lymphoma (HL):**

- Is a very specific type of cancer that derived from B-lymphocytes.

#### **2. Non-Hodgkin's Lymphoma (NHL):** Derived from B-Cells and T-Cells.

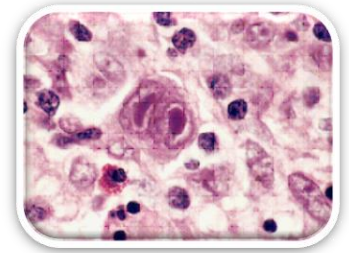
- B-Cell Lymphomas account for over 85% of all NHL.
- T-Cell Lymphomas account for over 15% of all NHL.

## Hodgkin's Lymphoma

- Usually affects young age from 1<sup>st</sup> to 3<sup>rd</sup> decades of life.
- Characterized by Painless peripheral adenopathy.
- Involves cervical and supraclavicular nodes.
- Less frequently involving the axillary and inguinal nodes.
- Distinguished from NHL by presence of **Reed-Sternberg cell (RS cell)**.

### **Reed-Sternberg cell (RS cell).**

**Classic RS cell:** Large cell with indistinct cell border, abundant eosinophilic cytoplasm, have bilobate nucleus, prominent nucleoli. This is the only malignant cell in Hodgkin's lymphoma. The other cells are reactive.



### **Grossly:**

- ❖ The affected lymph node is painless, enlarged, firm in consistency.
- ❖ The cut surface is grayish and fleshy.

### **Microscopic Picture :**

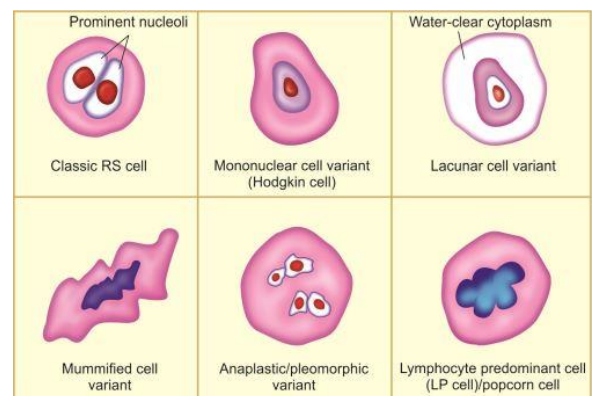
- Loss of nodular architecture.
- Replacement of lymphoid tissue by mixed benign (polymorphic) cells infiltrate associated with characteristic malignant **Reed-Sternberg cell**.

### **To make the diagnosis of Hodgkin's Lymphoma, 2 findings are needed:**

1. Reed- Sternberg cells. They **have a very characteristic immunostains:**
  - Positive for CD15, CD30.
  - Negative for leukocyte common antigen (CD45).
  - Negative for B-cell and T-cell antigen.
2. Inflammatory background.

### **Morphologic Variants of RS cell:**

1. Classic RS cells.
2. Mononuclear (Hodgkin) cell
3. Lacunar cell.
4. Mummified cell
5. Polymorphic (anaplastic ) RS cells.
6. Lymphohistiocytic (L&H) "popcorn" cell.



## **WHO classifications of Hodgkin's Lymphoma:**

### **A. Nodular lymphocyte predominance Hodgkin's lymphoma.**

### **B. Classical Hodgkin's lymphoma:**

- Nodular sclerosis classical Hodgkin's lymphoma.
- Mixed cellularity classical Hodgkin's lymphoma.
- Lymphocyte depletion classical Hodgkin's lymphoma.
- Lymphocyte-rich classical Hodgkin's lymphoma.

### **(A) Nodular Lymphocyte Predominant Hodgkin's Lymphoma**

- Characterized by lymphohistiocytic "**popcorn**" type cells.
- Classic RS cells are very rare.
- There are numerous small lymphocytes with or without histiocytes.

### **(B) Classic Hodgkin's Lymphoma**

#### **1. Nodular Sclerosis Classic Hodgkin's Lymphoma**

- The most common type.
- **Characterized by 2 features:**
  1. Presence of **lacunar cells**.
  2. Presence of **collagen bands** that divide the lymphoid tissue to nodules.

#### **2. Lymphocyte Rich Classic Hodgkin's Lymphoma**

- Usually localized, often in cervical L.N.
- Characterized by a large number of small reactive lymphocytes and small number of neoplastic R-S cells.
- Good prognosis.

#### **3. Lymphocyte Depleted Classic Hodgkin's Lymphoma**

- Characterized by a small number of small reactive lymphocytes and large number of neoplastic polymorphic RS cells.
- Bad prognosis.

#### **4. Mixed Cellularity Classic Hodgkin's Lymphoma**

- Characterized by a mixture of lymphocytes, plasma cells, eosinophils, histiocytes & RS cells.
- Prognosis is intermediate.

## **Prognosis Of Hodgkin Disease:**

**Depends upon** the age, symptoms, stage and histological type.

- **Age** ----- better prognosis in younger patients.
- **Histological type** ----- better prognosis in lymphocytic predominant > nodular sclerosis > mixed cellularity > lymphocytic depletion.
- **Stage** ----- lower stage has better prognosis.
- **Symptoms** ----- generalized symptomatic disease has worst prognosis.
- Overall; Good prognosis than Non-Hodgkin's lymphoma.

- **The causes of death:** are mainly due to disturbance of cell mediated immune response leading to increased susceptibility to infection as well as local compression of nearby organs.

### **Non-Hodgkin's Lymphoma (NHL)**

- Malignant proliferation of B or T-lymphocytes.
- Nodal or extra nodal (GIT, skin, lung, testis, salivary glands).
- May be localized or generalized lymphadenopathy.
- It can be disseminated to other tissues.
- Increase with age and common in male.

### **Risk Factors:**

1. AIDS.
2. Immunosuppressant drugs.
3. Autoimmune diseases.
4. Human T-lymphotropic virus type 1 (**HTLV1**) & **EBV**.
5. Environmental causes-----e.g. pesticides, fertilizers and others.
6. Some bacteria e.g. **Helicobacter Pylori** -----in gastric lymphoma.

### **WHO classification of non-Hodgkin's lymphoma**

- 1. Low Grade Type:** Slowly growing. **It Includes:**
  - Small lymphocytic.
  - Follicular lymphoma.
- 2. Intermediate Grade Type:** More rapidly growing. **It Includes:**
  - Diffuse large B-cell lymphoma.
- 3. High Grade Type:** Very rapidly growing. **It Includes:**
  - Lymphoblastic lymphoma.
  - Large cell immunoblastic lymphoma.
  - Small non cleaved (Burkitt's lymphoma).

### **Small Lymphocytic Lymphoma (SLL)**

- Diffuse replacement of nodal architecture by small atypical round lymphocytes with scant cytoplasm.
- **Origin:** B-cells (positive for CD19, CD20, CD23).

### **Follicular Lymphoma**

- Nodular or follicular pattern of B-cell type.
- May progress to diffuse type.
- Better prognosis than diffuse type.

### **Diffuse large B-cell Lymphoma**

- Diffuse replacement of nodal architecture by neoplastic large lymphoid cells.

- Capsular and extra capsular invasion.
- Worse prognosis than follicular variant.

**Lymphoblastic Lymphoma**

- High grade tumor ,affect male less than 20 years.
- Prominent mediastinal mass in 50-70% of cases.
- Microscopically: Usually T-Cell type, which distinguishes this tumor from most others.

**Large Cell Immunoblastic Lymphoma**

- **Pathogenesis:** Can be associated with auto-immune disorders (Rheumatoid arthritis, Sjögren syndrome), or other immune disorders.
- **AIDS patients** often get this type of lymphoma.
- **Microscopically:** Immunoblasts are identified by large nucleoli in the center of the cell & irregular nuclear contour.

**Burkitt's Lymphoma**

- Small non cleaved non-Hodgkin lymphoma.
- It is a special type of lymphoma that is endemic in some parts of Africa & sporadic in other areas.

**Site:** head and neck area ,**common in** children and young adults.

**Caused by** infection with Epstein Barr Virus (**EBV**).

**Two Types:** American, African.

**Grossly:** In African patients; involvement of maxilla or mandible is the commonest presentation.

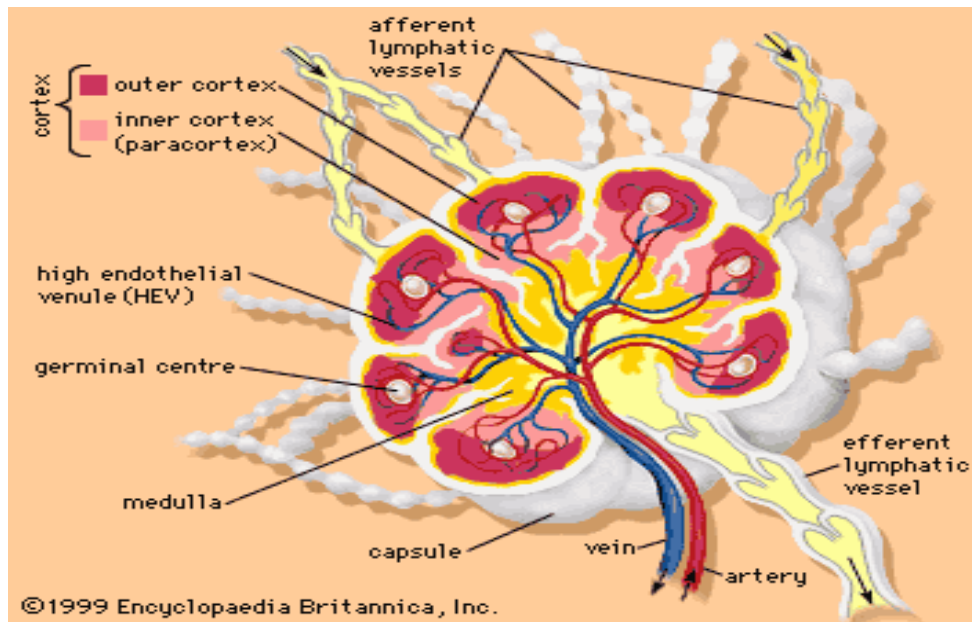
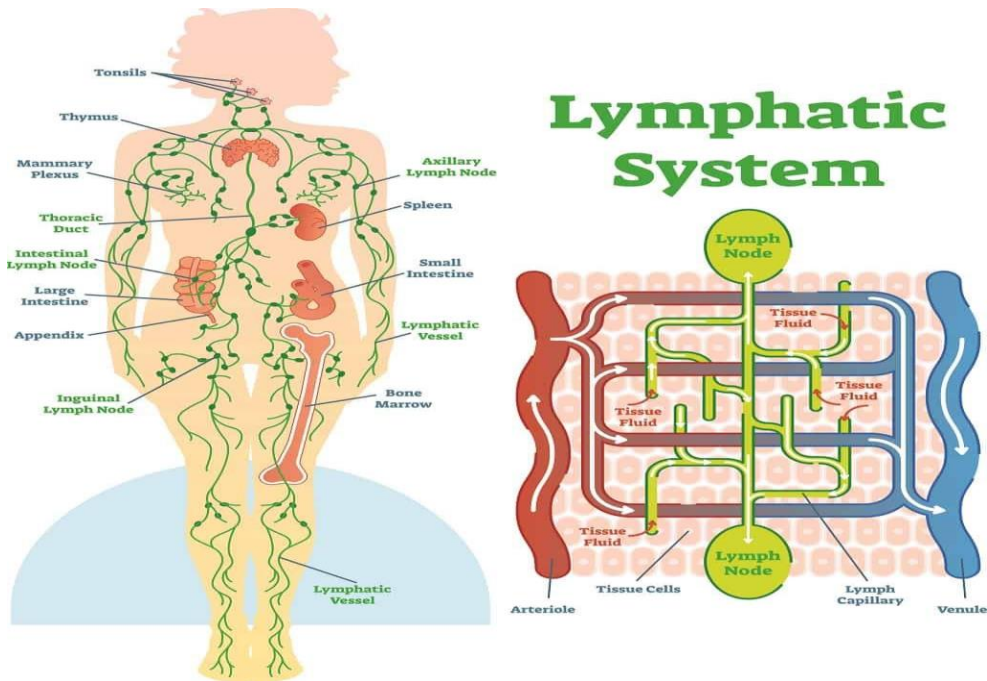
Abdominal tumors are more common in American patients.

**Histopathology:**

- Sheets of uniform medium sized lymphocytes with round nuclei, multiple basophilic nucleoli, course chromatin, scant to moderate basophilic vacuolated cytoplasm, laden with lipid droplet, minimal intervening stroma.
- Tangible body macrophages loaded with this lipid, appear as white stars against the blue sky produce a "**Starry Sky**" appearance.

.....


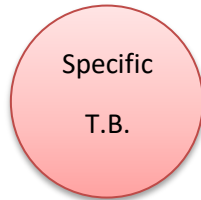
## Surgery of the lymph nodes and lymphatics



## Causes of lymphadenopathy:

1- Inflammatory: a) Acute lymphadenitis

b) Chronic lymphadenitis



- **Chronic non-specific lymphadenitis:** is the most common type of lymphadenitis. Caused by recurrent bacterial lymphadenitis. The lymph nodes are enlarged tender and firm in consistency

2- Neoplastic a) - primary → Lymphoma

b) - secondary → From metastatic carcinoma

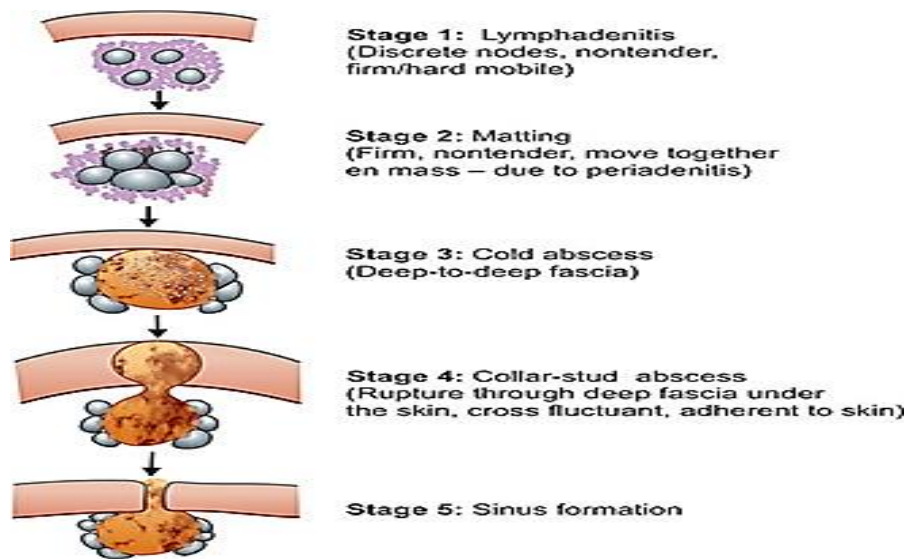
3- Blood diseases as leukemia.

## Tuberculous lymphadenitis

1- Lymphatic borne type

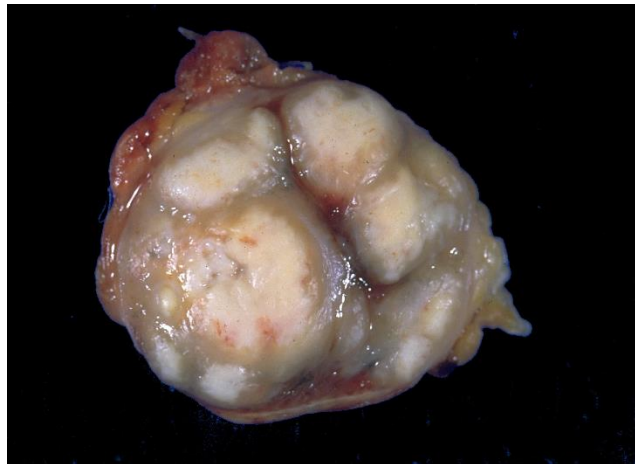
2- Blood borne type

### Lymphatic borne type



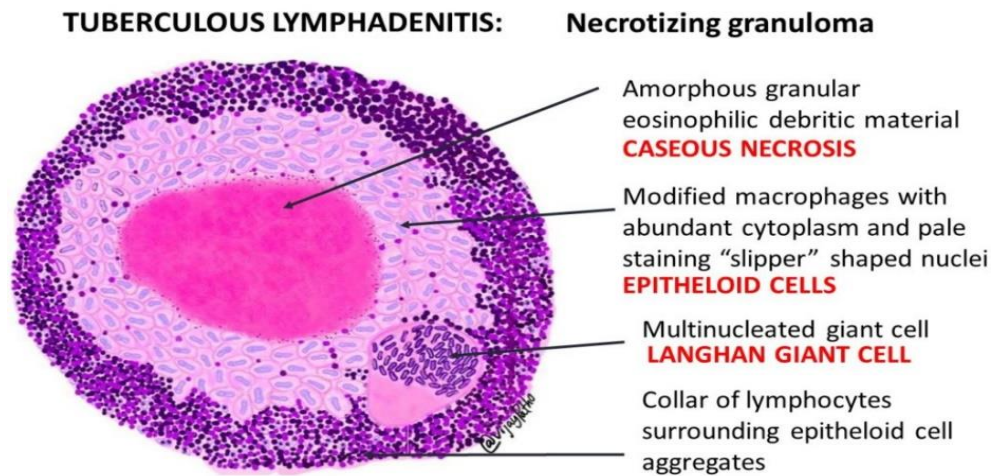
## Pathology

- **It is caused by Myco-bacterium T.B. organism.**
- Commonly affects young age group
- **Sites:** • the commonest groups of lymph nodes are **upper deep cervical nodes**.
  - Other groups are axillary, mediastinal and abdominal lymph nodes.
- The organism reaches the tonsils at first → then to the upper deep cervical lymph nodes via the afferent lymphatics → affecting the capsule of the lymph node **causing peri-adenitis and matting of the nodes**.
- The organism then reaches to the cortex → tubercles formation → **Caseation (necrosis)** → ending with **fibrosis and calcification**
- Accumulation of caseous material inside the lymph nodes may lead to formation of **Cold abscess**.
- Rupture of the caseous lymph node may lead to **sinus formation**
- T.B. affection of the skin may lead to **T.B.ulcer**



Gross picture of T.B. Lymphadenitis

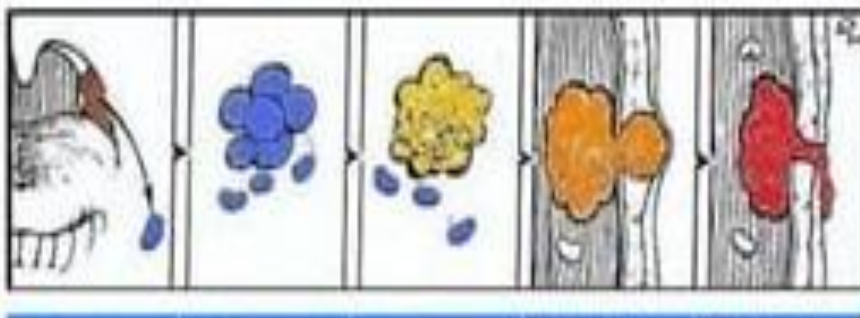
- **Microscopically:** epithelioid cells, fibroblasts, Langhans giant cells and fibrous tissue

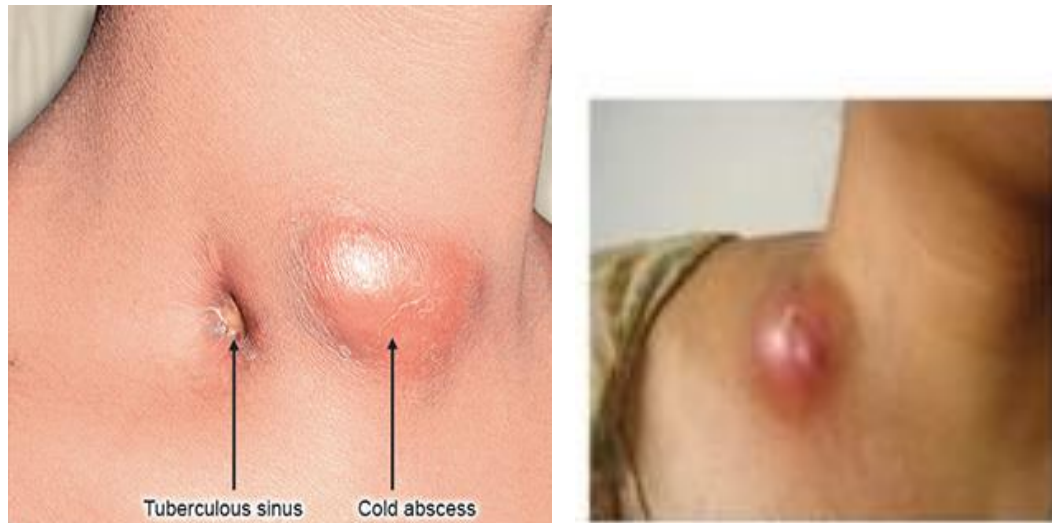


## **Complications of T.B. lymphadenitis**

### **1- Caseation and COLD ABSCESS**

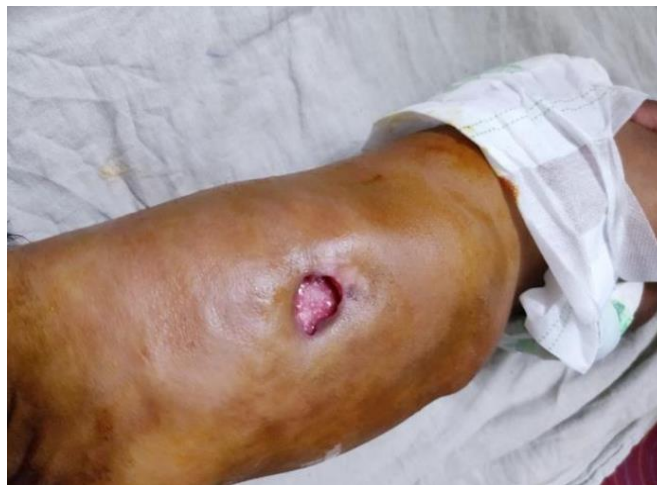- A group of lymph nodes filled with caseous material present in the upper part of the neck.
- It is called cold because it is not hot as pyogenic abscess
- The cold abscess is present deep to the deep fascia and may rupture leading to accumulation of the caseous material subcutaneous forming another abscess called collar-stud abscess
- The abscess is cystic in consistency
- The abscess may rupture to the skin causing sinus and ulcer





2- **T.B. sinus:** discharging caseous material

3- **T.B. ulcer** in the skin → has an undermined edge



T.B. ULCER

4- Spread to other groups of lymph nodes

5- Extensive fibrosis and calcification

### **Clinical picture of T.B. lymphadenitis**

- Night fever, night sweating and loss of weight
- The cervical lymph nodes are enlarged, firm, not tender, and matted together
- T.B. cervical lymphadenitis may present as a unilateral single or multiple painless lump, mostly located in the posterior cervical or supraclavicular region. The duration of lymphadenopathy at time of presentation is typically 1–2 months, varying from 3 weeks to 8 months

- Picture of cold abscess, sinus and undermined ulcer (as above).

## **Investigations**

### **Imaging techniques**

1- Chest X-ray → for pulmonary T.B. Chest X-ray findings may be positive in 10–40% of patients. However, the normal chest X-ray should not exclude the CTL diagnosis.

2- Neck ultrasound:

- The changes in size, shape (L/T ratio), echogenicity and morphology of the nodal hilum or cortex have been suggested as sonographic criteria for differentiation of benign pathologies from malignant. However,
- USG findings do not show disease-specific features. It can also be used as an imaging tool for the guided aspirations.
- Therefore, when combined with fine-needle aspiration, it has a very high sensitivity and specificity.

3- CT and MRI are valuable complementary techniques in evaluation of Lymphadenitis

- They accurately demonstrate the sites, pattern and extend of the disease. Imaging features are varied and nonspecific, although rim enhancement or calcification, if present, can be a strong indicator of the disease
- At CT, the affected nodes have center of low attenuation with an enhancing rim
- The non-enhancing areas indicate caseation, and the enhancing areas indicate granulation tissue with an inflammatory hypervascularity and increased vascular permeability.
- A fibro-calcified node is usually seen in patients who have been treated.

2- Tuberculin test → good negative test

3- FNAC: is a reliable method for diagnosis

- In fine-needle aspiration (FNA), a thin needle is inserted into an infected, swollen, superficial lymph node. Then, the taken aspirate material could be allocated for cytological examination, acid-fast bacilli (AFB) staining, culturing and/or molecular testing.
- Fine-needle aspiration cytology shows up a well-formed epithelioid granuloma and the presence of caseous necrosis.
- The sensitivity and specificity of FNA cytology in the diagnosis of tuberculous lymphadenitis are 88% and 96%, respectively.
- Combination of FNA cytology with the culture increases the diagnostic value.
- FNA material also subjected to Ziehl-Neelsen (ZN) staining for mycobacterial culture and molecular test

4- ***Molecular testing: Polymerase chain reaction (PCR)*** which is a nucleic acid amplification test, provide a rapid, specific and sensitive diagnosis of M. tuberculosis.

3- Biopsy of the affected lymph nodes → diagnostic (Langhan's giant cells, epithelioid cells, fibroblasts,..). Histopathologic examination and PCR of an excisional biopsy should be recommended only for patients in whom ***FNA-PCR*** is negative

5- Aspiration of cold abscess

### **Treatment**

• Anti-T.B. drugs as INH, Rifampicin, streptomycin in combination.

• **In case of cold abscess** →

1- Anti-T.B. drugs

2- Repeated aspiration in valvular manner and in non-dependent position to avoid sinus formation + installation of streptomycin inside

3- open drainage in resistant cases to aspiration. A non-dependent incision is used and keep the wound opened and closed later on without drain to avoid sinus formation

4- In resistant cases → Excision of the affected L.N.

• **In T.B. Ulcer** → Repeated dressing with streptomycin powder

• **In T.B. Sinus** → Excision of the affected lymph nodes.

---

### **Lymphangitis and lymphedema**

**Lymphangitis**: inflammation of the lymphatics

#### **Causes:**

1. Bacterial infections (most common): group A Streptococci – staph aureus
2. Fungal infections
3. Parasitic infestations: filaria
4. Physical or chemical injuries: trauma, radiation, injected irritants
5. On top chronic venous insufficiency

**Risk factors:** skin breaks, ulcers, insect bites, drug abuse, chronic lymphedema,..

#### **Clinical presentations:**

1. General: fever, chills, malaise, myalgia,..
2. Local:
  - Primary infection site: as wound, or ulcer,..
  - Red streaks: tender erythematous linear streaks extending proximally from the infection site towards the regional lymph

nodes. Associated with burning or throbbing pain along the affected vessels (Common With bacterial causes)

- Edema and warmth of the affected area
- Lymphadenitis and lymph nodes swellings



**Differential diagnosis:**

- a) Superficial thrombophlebitis
- b) Cellulitis and erysipelas
- c) DVT
- d) Allergic reactions

**Treatment:**

- a) Rest the affected limb
- b) Treat the original cause
- c) Antibiotics and NSAIDS

**What is lymphedema?**

lymphedema refers to tissue swelling caused by an accumulation of protein-rich fluid that's usually drained through the body's lymphatic system.

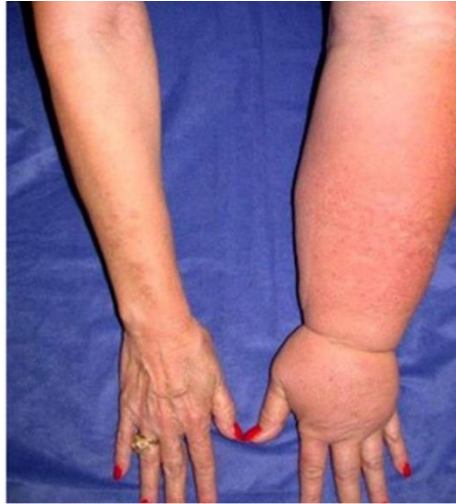**Causes**

**Primary:** abnormal development of lymphatic vessels

- I. Congenital lymphedema:
  - Milroy's disease: onset at birth – hypoplastic lymphatics – mostly in lower limbs. FLT4/ VEGFER3 mutations
- II. Lymphedema precox: most common primary type
  - Onset at puberty
  - FOXC2 or GJC2 gene mutations
  - Common in lower limbs
- III. Lymphedema tarda
  - Late onset ( > 35 years)

## Secondary lymphedema

- Surgery: breast cancer surgery – pelvic surgery (extensive lymphatics removal)  
recurrent cannulation of the affected limb
- Radiation therapy
- Trauma – **burns**
- Infections: filariasis – recurrent lymphangitis → scarring of the lymphatics
- OBESITY



lymphedema

How to manage?

- Pressure garments
- Physiotherapy
- Elevation of the affected limb
- Surgery: often difficult

**PLASMA CELL DISORDERS & LEUKEMIA**

Plasma cell disorders are neoplastic or potentially neoplastic diseases associated with the proliferation of a single clone of immunoglobulin-secreting plasma cells.

- ❖ They are characterized by the secretion of electrophoretically and immunologically homogeneous (monoclonal) proteins that represent intact or incomplete immunoglobulin molecules.
- ❖ Monoclonal proteins are commonly referred to as M proteins, myeloma proteins, or paraproteins.

**CLASSIFICATION OF PLASMA CELL PROLIFERATIVE DISORDERS**

<b>Monoclonal gammopathies of undetermined significance</b>
<b>Malignant monoclonal gammopathies</b>
❖ Multiple myeloma ❖ Waldenström's macroglobulinemia
<b>Heavy chain diseases</b>
<b>Cryoglobulinemia</b>
<b>Primary amyloidosis (AL)</b>

**MULTIPLE MYELOMA**

- ❖ Multiple myeloma is characterized by the neoplastic proliferation of a single clone of plasma cells engaged in the production of a monoclonal immunoglobulin.
- ❖ This clone of plasma cells proliferates in bone marrow and frequently invades the adjacent bone to produce extensive skeletal destruction that results in bone pain and fractures.

**Clinical Manifestations**

---

- a) *Skeletal involvement*: pain, reduced height, pathologic fractures, hypercalcemia
- b) *Anemia*: mainly caused by decreased erythropoiesis; produces weakness and fatigue
- c) *Renal insufficiency*: mainly caused by “myeloma kidney” from light chains or hypercalcemia, rarely from amyloidosis
- d) *Recurrent infections*: respiratory and urinary tract infections or septicemia caused by gram-positive or gram-negative organisms
- e) *Bleeding diathesis*: from thrombocytopenia or coating of platelets with M protein
- f) *Amyloidosis*: develops in 10%

**Physical Examination**

- 1) Pallor is the most frequent physical finding.
- 2) The liver is palpable in about 5% of patients and the spleen in 1%.
- 3) Tenderness may be noted at sites of bone involvement.
- 4) Radiculopathy may be caused by spinal compression fractures.

### **Treatment**

---

- 1) Treatment generally includes a combination of an oral alkylating agent (i.e., melphalan) and prednisone or vincristine/doxorubicin/dexamethasone.
- 2) Local radiation therapy can be used to relieve painful bone lesions, and zoledronic acid, 4 mg IV every month, decreases skeletal complications.

## **THE ACUTE LEUKEMIAS**

- A. Normal hematopoiesis requires tightly regulated proliferation and differentiation of pluripotent hematopoietic stem cells that become mature peripheral blood cells.
- B. Instead of proliferating and differentiating normally, the affected cell gives rise to progeny that fail to differentiate but continue to proliferate in an uncontrolled fashion.
- C. As a result, immature myeloid cells in acute myeloid leukemia (AML), or lymphoid cells in acute lymphoblastic leukemia (ALL)—often called blasts—rapidly accumulate and progressively replace the bone marrow, diminishing the production of normal red cells, white cells, and platelets.
- D. This loss of normal marrow function in turn gives rise to the common clinical complications of leukemia: anemia, infection, and bleeding.

### **Clinical Manifestations**

---

The acute leukemias have the following characteristics:

- 1) *Abrupt stormy onset.* Most patients present within 3 months of the onset of symptoms.
- 2) *Symptoms related to depression of normal marrow function.* These include fatigue, owing mainly to anemia; fever, reflecting an infection resulting from an absence of mature leukocytes; and bleeding (petechiae, ecchymoses, epistaxis, gum bleeding) secondary to thrombocytopenia)
- 3) *Bone pain and tenderness.* These result from marrow expansion with infiltration of the subperiosteum.
- 4) *Generalized lymphadenopathy, splenomegaly, and hepatomegaly.* These reflect dissemination of the leukemic cells; this occurs in all acute leukemias but is more pronounced in ALL.
- 5) *Central nervous system manifestations.* These include headache, vomiting, and nerve palsies resulting from meningeal spread; these features are more common in children than in adults and are more common in ALL than AML.

## Treatment

---

- 1) With the development of effective programs of combination chemotherapy and advances in hematopoietic stem cell transplantation, many patients with acute leukemia can be cured.

### Preparing the Patient for Therapy

- 2) Severe bleeding usually results from thrombocytopenia, which can be reversed with platelet transfusions.
- 3) Patients with fever and granulocytopenia should have blood cultures obtained; while awaiting culture results, infection should be assumed and broad-spectrum antibiotics begun empirically.
- 4) Before treatment, management in all patients should be aimed at preventing the tumor lysis syndrome. Patients should be hydrated, have their urine alkalinized with acetazolamide (500 mg/day), and be given allopurinol 100 to 200 mg orally three times per day before chemotherapy is initiated.

## THE CHRONIC LEUKEMIAS

### CHRONIC MYELOGENOUS LEUKEMIA

- ❖ Chronic myelogenous leukemia (CML), also called chronic myeloid leukemia, chronic myelocytic leukemia, and chronic granulocytic leukemia, is a clonal myeloproliferative disorder of the primitive hematopoietic stem cell that is characterized by overproduction of cells of the myeloid series, which results in marked splenomegaly and leukocytosis.
- ❖ A characteristic cytogenetic abnormality, the Philadelphia (Ph) chromosome, is present in the bone marrow cells in more than 90% of cases.

### **Clinical Manifestations**

---

- About 40 to 50% of patients diagnosed with CML are *asymptomatic* until the disease is found on routine physical examinations or blood tests.
- The symptoms of CML, when present, are due to *anemia and splenomegaly*: fatigue, weight loss, malaise, easy satiety, and left upper quadrant fullness or pain.
- Other rare presentations include gouty arthritis (from elevated uric acid levels), priapism (usually with marked leukocytosis or thrombocytosis), retinal hemorrhages, and upper gastrointestinal ulceration and bleeding (from elevated histamine levels due to basophilia).
- Splenomegaly, the most consistent physical sign in CML, occurs in 50 to 60% of cases.
- Lymphadenopathy is uncommon, as is infiltration of skin or other tissues.



## THE CHRONIC LEUKEMIAS

### CHRONIC MYELOGENOUS LEUKEMIA

- ❖ Chronic myelogenous leukemia (CML), also called chronic myeloid leukemia, chronic myelocytic leukemia, and chronic granulocytic leukemia, is a clonal myeloproliferative disorder of the primitive hematopoietic stem cell that is characterized by overproduction of cells of the myeloid series, which results in marked splenomegaly and leukocytosis.
- ❖ A characteristic cytogenetic abnormality, the Philadelphia (Ph) chromosome, is present in the bone marrow cells in more than 90% of cases.

#### **Clinical Manifestations**

---

- About 40 to 50% of patients diagnosed with CML are *asymptomatic* until the disease is found on routine physical examinations or blood tests.
- The symptoms of CML, when present, are due to *anemia and splenomegaly*: fatigue, weight loss, malaise, easy satiety, and left upper quadrant fullness or pain.
- Other rare presentations include gouty arthritis (from elevated uric acid levels), priapism (usually with marked leukocytosis or thrombocytosis), retinal hemorrhages, and upper gastrointestinal ulceration and bleeding (from elevated histamine levels due to basophilia).
- Splenomegaly, the most consistent physical sign in CML, occurs in 50 to 60% of cases.
- Lymphadenopathy is uncommon, as is infiltration of skin or other tissues.

### CHRONIC LYMPHOCYTIC LEUKEMIA

Chronic lymphocytic leukemia (CLL) is a neoplasm characterized by accumulation of monoclonal lymphocytes of B-cell origin. The cells accumulate in the bone marrow, lymph nodes, liver, spleen, and occasionally other organs.

#### **Clinical Manifestations**

---

- 1) Most patients with CLL are *asymptomatic*, and the disease is diagnosed when absolute lymphocytosis is noted in the peripheral blood.
- 2) Symptoms such as *fatigue, lethargy*, loss of appetite, weight loss, and reduced exercise tolerance are nonspecific.
- 3) The most common *infections* are sinopulmonary.

- 4) The major physical findings relate to infiltration of the reticuloendothelial system. Lymphadenopathy with discrete, rubbery, mobile lymph nodes is present in two thirds of patients at diagnosis.
- 5) Enlargement of the liver or spleen is less common at diagnosis.

### **Treatment**

---

- 1) The major therapeutic questions for CLL are when to treat and which therapeutic regimen to use. Patients with CLL are usually older, and the prognosis of the disease is variable.
- 2) Treatment of early-stage CLL is delayed until the disease progresses.
- 3) Because CLL is accompanied by immunodeficiency, life-threatening infections may occur. Therefore, febrile patients must be evaluated carefully.
- 4) Immune hemolytic anemia or immune thrombocytopenia may develop as complications of CLL. Treatment of these conditions is with glucocorticoids (e.g., prednisone, 1 mg/kg PO daily) or chemotherapy, or both.

### **Clinical pathology of Polycythemia & benign WBCs disorders**

**Polycythemia:** Polycythaemia is defined as an increase in the hemoglobin concentration above the upper limit of normal for the patient's age and sex. Primary polycythemia (polycythemia vera, PV) is a clonal disorder characterized by proliferation of erythrocytic series. The granulocytic and megakaryocytic series are also affected to a lesser extent. Primary polycythemia usually affects older subjects with equal sex incidence. The manifestations are mainly due to increase blood volume and increase viscosity which predispose to Thrombotic complications

**Laboratory features of PV:** Hemoglobin, RBCs count and PCV are high. Increased red cell mass (> 35 ml/kg in male, >32 ml/kg in female). Leukocytosis in >50% of cases (mostly neutrophils). Basophilia and eosinophilia are common. Increased platelet count (thrombocytosis) in >50% of cases. Normal arterial O<sub>2</sub> saturation (>92%). Decreased serum erythropoietin. PV is usually associated with acquired mutations of the genes that encode the tyrosine proteins, Janus-associated kinase 2 (JAK2). The most important two major diagnostic criteria of PV according to WHO: 1- High Hemoglobin, high hematocrit (or high red cell mass). 2- Mutation in JAK2

**Differential diagnosis of PV:** primary polycythemia should be differentiated from secondary polycythemia. The causes of secondary polycythemia include:

1- Hypoxia: low O<sub>2</sub> tension stimulates red cell production by increasing erythropoietin synthesis. This may be due to high altitude, pulmonary diseases as emphysema and cyanotic heart disease, smoking...

2- Tumor: hypernephroma or hepatoma due to increase erythropoietin production.

3-Non neoplastic renal disease: as hydronephrosis, renal cysts

Secondary polycythemia is characterized by mild increase of RBCs, hemoglobin and hematocrit. WBCs and platelet count are normal. Arterial oxygen saturation is decreased in cases due to hypoxia. JAK 2 mutation is absent. Erythropoietin level is increased.

**Neutrophilia:** Absolute neutrophils count (PMN) more than 7000/cmm in adult. The WBCs may show shift to left (↑ number of immature series as band(>5%),metamyelocytes and even myelocytes). Causes include acute pyogenic bacterial infection (Staph, strept,..),Tissue damage or necrosis: (infarction ,trauma, operations,..),malignancy( specially rapidly growing necrotic tumors complicated by infection) and myeloproliferative disorders as polycythemia and CML. **Neutropenia:** absolute neutrophil count less than 2000/cmm in adults. In mild cases (>1500/cmm) no symptoms are found. In severe cases(<500/cmm) symptoms are found and include fever, sweating, infective lesions in mouth and throats. Causes include drugs, Infection: (viral as Influenza, hepatitis...), hypersplenism, aplastic anemia, or Idiopathic

**Lymphocytosis:** absolute lymphocytic count more than 3500/cmm in adult. Causes include viral infections:( CMV, infectious mononucleosis, influenza, hepatitis,), chronic lymphocytic leukemia and Lymphoma (non-Hodgkin lymphoma)

**Lymphopenia:** Absolute lymphocytic count less than 1500/cmm. Causes include corticosteroid and immunosuppressive drugs; Irradiation; pancytopenia. HIV and covid-19 infections

**Eosinophilia:** Absolute eosinophilic count more than 500/cmm in adult. Causes include allergic diseases; parasitic diseases; Hodgkin disease and myeloproliferative disorders as polycythemia

**Infectious Mononucleosis (IM):** This is infectious disease caused by Epstein-Barr (EB) virus. It is transmitted by droplet infection. Clinical Picture: Fever, sore throat, generalized lymphadenopathy affecting superficial LNs (cervical is the commonest followed by other LNS) Laboratory findings of infectious mononucleosis: Total leucocytic count is usually increased (may reach 20,000/cmm). The absolute lymphocytic count is increased with the appearance of atypical lymphocyte (large with eccentric nucleus); hemoglobin, platelet count and ESR are usually normal. Atypical lymphocytes may also found to a less extent in cytomegalovirus infection, toxoplasma, hepatitis and other viral infections. Heterophil antibodies are found in IM. These antibodies react against sheep RBCs or horse RBCs and develop during the second or third weeks.it include: Paul-Bunnell test:(Ab against sheep RBC, not specific) or monospot test: (Ab against horse RBCs ,more specific), however its sensitivity is low in children below 4 years .EB- virus antibodies are detected . These antibodies are more sensitive and specific than heterophil antibodies. They are two types: Anti-viral capsid antibody (VCA) : develops in acute infection (specially IgM) and Anti EB nuclear antigen: develops late (old infection) and persists for life



## **Clinical pathology of Leukemia**

**Acute leukemia (AL):** Malignant proliferation of BM blast cells. (Normal blast cells in bone marrow is about 3%). Acute leukemia is normally defined as the presence of 20% or more of blast cells in the bone marrow or blood at clinical presentation. AL is further subdivided into two major types, acute myeloid leukemia (AML) and acute lymphoblastic leukemia (ALL). This classification is based on: 1- Morphology: Myeloblast: contain many nucleoli. Characteristic acidophilic granules may be found in cytoplasm (Auer rod) . Lymphoblast: contain few nucleoli and Auer rod is absent. 2- Cytochemical stains: AML are myeloperoxidase positive, and ALL are myeloperoxidase negative. 3- Immunological markers: using antibodies to detect specific antigens on blast cells. Clinical features of AL include anemia, infection in mouth, throat and other sites with fever and purpura with bleeding manifestations

Laboratory finding of AL: Moderate to marked normocytic normochromic anemia; Moderate to marked Thrombocytopenia; Total WBCs: is usually increased and may reach up to 200,000/cmm Blood film typically show variable number of blasts cells. Bone marrow is hypercellular with blast cell 20% or more.

**Chronic lymphoid leukemias:** This group is characterized by chronic persistent lymphocytosis and subtypes can be distinguished by morphology, Immunophenotyping and cytogenetics. Chronic lymphocytic leukemia (CLL) is by far the most common of chronic lymphoid leukemias. It occurs in old age with high incidence between 60 and 80 years. The disease may be asymptomatic and diagnosed accidentally when routine blood test is done for another reason. Symmetrical enlargement of lymph nodes is the most frequent sign. Splenomegaly and hepatomegaly are usual in later stages.

**Laboratory findings of CLL:** Leukocytosis varying from 20,000 to 250,000/cmm. Absolute lymphocytosis which is usually more than 10,000/cmm and is persistent. Between 70-99% of WBCs in blood film appear as small mature lymphocytes. Smudge or smear cells are also found. Normocytic anemia is present in late stages as a result of BM infiltrations. In some cases, there is autoimmune hemolytic anemia with positive coombs' test. Thrombocytopenia is found in late stages. Bone marrow: shows lymphocytic infiltration. Lymphocytes comprise more than 30% of all cells. Serum immunoglobulins concentrations are reduced. Serum LDH is increased specially in those with poor prognosis. Immunophenotyping reveals that CLL is mostly B-cells with a specific diagnostic markers.

**Chronic myeloid leukemia (CML)** is a myeloproliferative disease characterized by proliferation of mature and immature myeloid cells. It may be due to reciprocal translocation between chromosome 9 and 22 resulting in abnormal chromosome 22 which is called Philadelphia chromosome, and formation of BCR-ABL oncogene, leading to malignant proliferation of myeloid cells. There is gradual onset of anemia, hemorrhagic manifestations due to abnormal platelet function and huge splenomegaly. Laboratory findings of CML: Leukocytosis usually above 50,000/cmm and may reach 500,000/cmm or more. Granulocytosis involves all granulocytic series including

neutrophils (around 30-70%), myelocytes (20-50%) and other cells as metamyelocytes and band cells. Blast cells are rare (usually <5%) or absent. Basophilia and eosinophilia are usually found. There is normocytic normochromic anemia. Platelet count is usually increased (initial thrombocytosis) but later on is decreased. Neutrophil alkaline phosphatase score is low. Bone marrow is hypercellular due to hyperplasia of granulocytic series. Ph chromosome is present in blood or BM in more than 90% of cases. BCR-ABL oncogene is detected

Differential diagnosis of chronic myeloid leukemia: CML should be differentiated from leukemoid reaction. The latter is used to describe excessive leukocytosis with shift to left (presence of immature cells) due to non-leukemic disorders as in cases of severe infection. It may resemble leukemia and hence its name (leukemoid reaction). In leukemoid reaction total WBCs is moderately high (<50,000); eosinophilia and basophilia are absent, neutrophil alkaline phosphatase score is high and Ph chromosome is absent.

**Multiple myeloma (MM):** Neoplastic proliferation of plasma cells throughout the bone marrow. This proliferation produces either a complete immunoglobulin and/or incomplete immunoglobulin (light chain). IgG myeloma is the commonest (50-60 %); IgA myeloma is found in 25% cases; Light chain disease is present in 20% of cases; IgD and IgE myeloma are rare. **Diagnosis of MM:** Diagnosis of MM depend mainly on three principal findings:

1-Monoclonal band: present in serum protein electrophoresis (more than 3 gm/dl in serum); or in concentrated urine electrophoresis (in cases light chain disease).

2- Bone marrow: increase plasma cells (>10%) with many mitotic figures.

3- Related organ or tissue damage: Hypercalcemia, renal impairment, anemia and bone affection with demonstration of osteolytic lesions in bone.

CRAB: high calcium, renal affection, anemia, bone lesion

Immunochemical studies: Identification of the type of immunoglobulin (IgG or, IgA,..) and the type of light chain (Kappa or lambda) is very important in diagnosis and in prognosis. (Lambda light chain has poorer prognosis than kappa). This identification is done by immunofixation.

Other laboratory findings in MM: Increase total protein (>8 gm/dl). Bence Jones (BJ) protein is found in urine (in 2/3 cases). Serum free light chain (sFLC) ratio is altered. Serum calcium is increased (due to release of calcium to blood from the osteolytic bone lesions). Serum phosphorus may be also increased. Alkaline phosphatase is normal (bone lesion is osteolytic and not osteoblastic). Urea and creatinine may be increased due to renal affection. Hematological changes: Marked increase of ESR, and normocytic normochromic anemia.

**Smoldering (Asymptomatic myeloma):** It is diagnosed when the monoclonal protein in serum is more than 3 gm/dl and/or 10% or more of plasma cells are found in bone marrow. But there is no organ damage (No CRAB)

**Benign monoclonal gammopathy:** monoclonal protein may be found in serum in benign conditions and not only multiple myeloma. It can be seen in old age and chronic diseases, Without evidence of myeloma. It is also named Monoclonal gammopathy of undetermined significance(MGUS).In about 1% or more, they may develop MM thus follow up of these patient is needed .It is differentiated from multiple myeloma by these laboratory findings: Monoclonal protein in serum is less than 3 gm/dl; BJ protein is absent; normal serum calcium and normal renal function; absence of bone lesions; normal plasma cells in bone marrow ( less than 10%);anemia is usually absent and ESR is normal .Serum free light chain (sFLC) ratio is normal.

---

## **APPROACH TO THE PATIENT WITH BLEEDING AND THROMBOSIS**

### **BLEEDING DISORDERS**

- ❖ These disorders are characterized clinically by abnormal bleeding, which may either be spontaneous or become evident after some inciting event (e.g., trauma or surgery).
- ❖ Abnormal bleeding may have as its *cause (1) a defect in the vessel wall, (2) platelet deficiency or dysfunction, or (3) a derangement of coagulation factors.*

### **EVALUATION OF PATIENTS WITH HEMOSTATIC DISORDERS**

#### ***HISTORY***

---

- a) A detailed history is crucial for determining whether a bleeding disorder is present and whether it is likely to be congenital or acquired, mild or severe, and involving primary or secondary hemostasis.
- b) Prolonged bleeding after challenges such as dental extractions, circumcision, menstruation, labor and delivery, trauma, or surgery may suggest an underlying bleeding disorder, especially if blood transfusion or hospital admission for control of hemostasis is required.
- c) Self-reporting of easy bruising and prolonged bleeding with minor cuts is often noninformative unless accompanied by more serious bleeding events.
- d) A detailed family history may reveal evidence to support an inherited bleeding disorder.
- e) Acquired bleeding disorders may be suggested by recent onset and comorbid conditions (liver disease, alcohol consumption, autoimmune disease) or commonly implicated medications.

## PHYSICAL EXAMINATION

---

- 1) Primary hemostasis defects are suggested by mucosal bleeding and bruising.
- 2) Bruising manifests as areas (<2 mm) of subcutaneous bleeding that do not blanch with pressure, called petechiae; larger patches (<1 cm), designated purpura; or extensive areas of bruising (>1 cm), called ecchymoses
- 3) Petechiae typically present in areas that are subjected to increased hydrostatic force typically involving the lower legs or the periorbital area after coughing or vomiting.

## ABNORMALITIES OF PLATELET AND VASCULAR FUNCTION

### THROMBOCYTOPENIA

- a) Thrombocytopenia is defined as a platelet count of <140,000/microliter
- b) Thrombocytopenia may be due to either increased platelet destruction or utilization, abnormal platelet distribution (an enlarged splenic pool), or decreased platelet production
- c) Assuming normal platelet function, the symptoms and signs expected with various platelet counts are as follows: greater than 50,000/ $\mu$ L, no symptoms or signs, although patients may bleed longer with major trauma; 25,000 to 50,000/ $\mu$ L, petechiae and bruising with minor trauma; 10,000 to 25,000/ $\mu$ L, spontaneous petechiae and bruising greater on the lower extremities and menorrhagia; less than 10,000/ $\mu$ L, prominent bruising, mucosal bleeding (epistaxis, gum bleeding, gastrointestinal [GI] or genitourinary [GU] bleeding), and a risk for central nervous system (CNS) bleeding.

### CAUSES OF THROMBOCYTOPENIA

#### (I) INCREASED PLATELET DESTRUCTION OR UTILIZATION

##### Immune destruction

- ❖ Autoantibodies: ITP, disease-associated IT (collagen disease, lymphoproliferative disorders)
- ❖ Drug-induced IT: quinidine, quinine, sulfonamides, gold, etc.
- ❖ Infection—HIV, hepatitis, cytomegalovirus, Epstein-Barr virus

##### Nonimmune destruction or platelet removal

- ❖ Infection (bacterial, viral, malarial)
- ❖ Thrombotic thrombocytopenic purpura/hemolytic-uremic syndrome
- ❖ Disseminated intravascular coagulation

***Platelet redistribution (enlarged splenic pool)***

- ❖ Congestive splenomegaly
- ❖ Other (non-Hodgkin's lymphoma, Gaucher's disease, etc.)

**(II) DECREASED PLATELET PRODUCTION**

- ❖ Myeloproliferative disorders (acute or chronic leukemias, multiple myeloma, myelofibrosis)
- ❖ Lymphoproliferative disorders (non-Hodgkin's lymphoma, CLL)
- ❖ Aplasia or hypoplasia (idiopathic, drug induced, radiation)
- ❖ Drugs (chemotherapy, thiazides, alcohol, etc.)

**IMMUNE THROMBOCYTOPENIAS**

***Chronic Immune Thrombocytopenic Purpura***

---

Chronic immune thrombocytopenic purpura (ITP) is an autoimmune disorder manifested by immune-mediated thrombocytopenia. The diagnosis is one of exclusion and is based on American Society of Hematology guidelines

**AMERICAN SOCIETY OF HEMATOLOGY CRITERIA FOR THE DIAGNOSIS OF CHRONIC IMMUNE THROMBOCYTOPENIC PURPURA: DIAGNOSIS OF EXCLUSION**

- 1) History compatible with the diagnosis of chronic ITP.
- 2) Normal physical examination findings except for signs of thrombocytopenia (petechiae, purpura, or mucosal bleeding); no adenopathy or splenomegaly.
- 3) Complete blood count showing isolated thrombocytopenia with large platelets but no anemia unless bleeding or immune hemolysis is present
- 4) Bone marrow examination showing normal or increased numbers of megakaryocytes.
- 5) No clinical or laboratory evidence for other causes of thrombocytopenia.

**Diagnosis**

The diagnosis is one of exclusion and other causes of thrombocytopenia must be excluded

**Differential Diagnosis**

- ❖ Because an ITP-like syndrome can be seen in patients with HIV or hepatitis C infection, appropriate testing is indicated in at-risk individuals.
- ❖ Secondary ITP may be induced by drugs or occur in patients with collagen vascular disease , lymphoproliferative disorders.

## **Treatment**

- 1) Not all patients with immune thrombocytopenia require treatment. Initial therapy, when indicated, consists of glucocorticoids (typically prednisone 1 mg/kg/d) with the addition of IVIg in nonresponders or if the patient is bleeding.
- 2) Most patients who are treated respond to therapy within 1-3 weeks. Of the patients who respond to glucocorticoid therapy, 30%-40% will relapse during a steroid taper, and these individuals are considered to have chronic ITP.
- 3) ITP patients who are refractory to initial therapy or relapse are treated either with splenectomy or immunosuppressive therapy.

## ***Disease-Associated Immune Thrombocytopenia***

---

### *❖ Collagen Vascular Disease*

Thrombocytopenia is noted in 14 to 26% of patients with systemic lupus erythematosus and is seen much less frequently with other collagen vascular diseases.

### *❖ Lymphoproliferative Disorders*

A low platelet count is commonly seen in patients with lymphoproliferative disorders. In most cases it is due to decreased platelet production because of marrow infiltration or the effects of treatment. However, immune thrombocytopenia is sometimes noted, particularly in individuals with chronic lymphocytic leukemia or indolent non-Hodgkin's lymphoma.

## ***Thrombotic Thrombocytopenic Purpura***

---

Thrombotic thrombocytopenic purpura (TTP) is a life-threatening disorder characterized by platelet aggregation and thrombosis in the microvasculature; it results in thrombocytopenia, hemolytic anemia, organ ischemia, and unless treated, a mortality rate higher than 90%.

Hemolytic-uremic syndrome (HUS) is a clinically similar disorder that primarily affects children and is marked by a predominance of renal failure.

## **Clinical Manifestations**

- ❖ The classic TTP “pentad” of signs and symptoms includes (1) *thrombocytopenia* (2) *microangiopathic hemolytic anemia* (3) *renal insufficiency*, which is generally mild with moderate increases in serum creatinine and urine protein levels (4) *fever* (5) *neurologic abnormalities*, which range from mild headache and disorientation to severe symptoms such as hemiparesis, seizures, focal neurologic deficits, coma, and death.

## **Treatment**

- 1) Rapid treatment of TTP is critical to prevent serious morbidity or mortality from thrombotic complications. Plasma exchange with fresh-frozen plasma is the mainstay of therapy.
- 2) The addition of glucocorticoids has become common practice, ranging from prednisone, 1 mg/kg PO daily, to methylprednisolone, 1 g IV daily.

## **HEMORRHAGIC DISORDERS: COAGULATION FACTOR DEFICIENCIES**

### **COAGULATION DEFICIENCIES**

- ❖ Severe coagulation deficiencies, or coagulopathies, typically are characterized by the development of excessive bleeding or bruising that is unprovoked or, more commonly, is precipitated by trivial incidental or surgical trauma.
- ❖ These disorders result from either congenital or acquired deficiencies of clotting factors. The latter, which are much more common and relatively straightforward.

### **HEREDITARY HEMOPHILIAS**

---

#### **Definition**

The hemophilias include hemophilia A, caused by a deficiency of clotting protein factor VIII (antihemophilic factor), and hemophilia B, caused by a deficiency of factor IX or Christmas factor

#### **Clinical Manifestations**

- a) Clinically, hemophilia A and hemophilia B are indistinguishable. The disease phenotype correlates with the residual activity of FVIII or FIX and can be classified as severe (< 1%), moderate (1–5%), or mild (6–30%). In the severe and moderate forms, the disease is characterized by bleeding episodes into the joints (hemarthroses), soft tissues, and muscles after minor trauma or even spontaneously.
- b) The disease is more evident when children begin to walk or crawl. In the severe form, the most common bleeding manifestations are the recurrent hemarthroses, which can affect every joint but mainly affect knees, elbows, ankles, shoulders, and hips.
- c) Acute hemarthroses are painful, and clinical signs are local swelling and erythema. To avoid pain, the patient may adopt a fixed position, which leads eventually to muscle contractures.

## **Treatment**

- 1) patients with mild to moderate hemophilia A and a minor bleeding episode can be treated with DDAVP (Desmopressin, diamino-8-D-arginine vasopressin) which stimulates release of vWF(factor VIII) from endothelial cells and shortens a prolonged BT, which increases plasma levels by three- to fivefold within 30 minutes, with a half-life of 8-12 hours.
- 2) Patients with mild to moderate hemophilia A with major bleeding episodes or those with severe hemophilia A with any prolonged source of hemorrhage require FVIII replacement for bleeding challenges.
- 3) This treatment may consist of either purified FVIII concentrate from pooled plasma or recombinant FVIII (rFVIII).

## ***HEREDITARY VON WILLEBRAND'S DISEASE***

---

### **Definition**

- a) Von Willebrand's disease (vWD), results from an inherited qualitative or quantitative defect of vWF. The inheritance of most forms of vWD is autosomal dominant.
- b) The spectrum of bleeding is broad and is related to the inherited form.
- c) vWF has two important functions: to facilitate adherence of platelets to injured vessel walls and to stabilize factor VIII in plasma.

### **Clinical Manifestations**

- a) Most patients with vWD have mild disease that may go undiagnosed until trauma or surgery occurs.
- b) Menorrhagia affects 50 to 75% of affected women and may be the initial symptom.
- c) The use of aspirin or NSAIDs with anti-platelet aggregation effects may exacerbate the symptoms.

### **Treatment**

- 1) The goals of therapy for vWD consist of correcting the deficiencies in vWF protein activity to greater than 50% of normal and in factor VIII activity to levels appropriate for the clinical situation.
- 2) Replacement therapy with viral-attenuated, intermediate-purity or high-purity factor VIII concentrates containing an incomplete complement of high-molecular-weight multimers of vWF.

## **DISSEMINATED INTRAVASCULAR COAGULATION**

### **Definition**

- ❖ DIC, also referred to as consumptive coagulopathy, is a clinicopathologic syndrome characterized by widespread intravascular fibrin formation in response to excessive blood protease activity that overcomes the natural anticoagulant mechanisms.
- ❖ DIC is diagnosed in almost half of pregnant women with abruptio placentae or with amniotic fluid embolism.

### **MAJOR CAUSES OF DISSEMINATED INTRAVASCULAR COAGULATION**

<b><u>Infections</u></b>
<ul style="list-style-type: none"><li>❖ Gram-negative bacterial sepsis</li><li>❖ Other bacteria, fungi, viruses, Rocky Mountain spotted fever, malaria</li></ul>
<b><u>Immunologic reactions</u></b>
<ul style="list-style-type: none"><li>❖ Transplant rejection</li></ul>
<b><u>Obstetric complications</u></b>
<ul style="list-style-type: none"><li>❖ Amniotic fluid embolism</li><li>❖ Retained dead fetus</li><li>❖ Toxemia, preeclampsia</li><li>❖ Septic abortion</li></ul>
<b><u>Malignancies</u></b>
<ul style="list-style-type: none"><li>❖ Pancreatic carcinoma</li></ul>
<b><u>Liver failure</u></b>
<b><u>Acute pancreatitis</u></b>
<b><u>Trauma, shock</u></b>
<ul style="list-style-type: none"><li>❖ Crush injury</li><li>❖ Burns</li><li>❖ Fat embolism</li></ul>

### **Pathophysiology**

- a) DIC is primarily a thrombotic process, although its clinical manifestation may be widespread hemorrhage in acute, fulminant cases.
- b) The basic pathophysiology, regardless of cause, is entry into the circulation of procoagulant substances that trigger systemic activation of the coagulation system and platelets and subsequent disseminated deposition of fibrin-platelet thrombi.
- c) In DIC, tissue factor gains access to blood by tissue injury, its elaboration by malignant cells, or its expression on the surface of monocytes and endothelial cells by inflammatory mediators.
- d) Tissue factor triggers generation of the coagulation protease thrombin, which induces fibrin formation and platelet activation.

- e) In acute, uncompensated DIC, coagulation factors are consumed at a rate in excess of the capacity of the liver to synthesize them, and platelets are consumed in excess of the capacity of bone marrow megakaryocytes to release them.
- f) Increased fibrin formation in DIC stimulates the process of secondary fibrinolysis, in which plasminogen activators generate plasmin to digest fibrin (and fibrinogen) into fibrin(ogen) degradation products (FDPs).

### **Clinical Manifestations**

- 1) The clinical manifestations of DIC are determined by the nature, intensity, and duration of the underlying stimulus.
- 2) Gangrene of the digits or extremities, hemorrhagic necrosis of the skin, or purpura fulminans may also be manifestations of DIC.
- 3) Bleeding is the most common clinical finding in acute, uncompensated DIC. Bleeding can be limited to sites of intervention or anatomic abnormalities, but it tends to be generalized in more severe cases, including widespread ecchymoses and diffuse oozing from mucosal surfaces and orifices.

### **Treatment Of Disseminated Intravascular Coagulation**

- 1) Identify and eliminate the underlying cause.
- 2) No treatment if mild, asymptomatic, and self-limited.
- 3) Blood component therapy Indications: active bleeding or high risk for bleeding, Fresh-frozen plasma Platelets.
- 4) Drug therapy Indications: Heparin for DIC manifested by thrombosis or acrocyanosis; antifibrinolytic agents generally contraindicated except with life-threatening bleeding and failure of blood component therapy.

<b>THROMBOTIC DISORDERS: HYPERCOAGULABLE STATES</b>
---

- a) The hypercoagulable states, also referred to as thrombophilias, encompass a group of inherited or acquired conditions that cause a pathologic thrombotic tendency or risk for thrombosis.
- b) The primary hypercoagulable states are caused by quantitative or qualitative abnormalities in specific coagulation proteins that induce a prothrombotic state. Most of these disorders involve inherited mutations that lead to either (1) deficiency of a physiologic antithrombotic factor or (2) increased level of a prothrombotic factor.
- c) The secondary hypercoagulable states, a diverse group of mostly acquired conditions, cause a thrombotic tendency by complex, often multifactorial mechanisms.

## **PRIMARY HYPERCOAGULABLE STATES**

### **DEFICIENCY OF ANTITHROMBOTIC FACTORS**

- ❖ Antithrombin (III) deficiency
- ❖ Protein C deficiency
- ❖ Protein S deficiency

### **INCREASED PROTHROMBOTIC FACTORS**

- ❖ Prothrombin Gene Mutation
- ❖ Activated Protein C Resistance

## **Clinical Manifestations**

- a) The primary hypercoagulable states are associated with predominantly venous thromboembolic complications.
- b) Deep venous thrombosis of the lower extremities and pulmonary embolism are the most frequent clinical manifestations.
- c) More unusual sites of venous thrombosis include superficial thrombophlebitis and mesenteric and cerebral venous thrombosis, venous thrombosis in the arm and hepatic vein thrombosis also known as Budd-Chiari syndrome.
- d) Arterial thrombosis involving the coronary, cerebrovascular, and peripheral circulations is not linked to any of the primary hypercoagulable states.
- e) The initial episode of venous thromboembolism can occur at any age in patients with primary hypercoagulable states, but it typically takes place in early adulthood.
- f) Positive family histories of thrombosis can frequently be elicited.

## **Treatment**

- 1) The initial treatment of acute venous thrombosis or pulmonary embolism in patients with primary hypercoagulable states is not different from that in patients without genetic defects
- 2) As in patients without known thrombophilia, thrombolytic therapy should be considered after massive venous thrombosis or pulmonary embolism
- 3) Acute management is initiated with at least 5 days of unfractionated or low-molecular-weight heparin.

- 4) Oral anticoagulation with warfarin can be started on the first day of heparin use and continued for at least 6 months in patients with venous thromboembolism in the absence of triggering factors (e.g., postoperative state), with regulation of the dose to maintain an international normalized ratio (INR) of the prothrombin time between 2.0 and 3.0
  - 5) Continuing oral anticoagulant prophylaxis beyond the initial 6 to 12 months after an acute episode of venous thromboembolism must be weighed against continued exposure of the individual patient to the significant risk for bleeding complications. Patients with primary hypercoagulable states who have had two or more thrombotic events should receive indefinite or lifelong prophylactic anticoagulation with warfarin.
  - 6) Indefinite or lifelong anticoagulation is probably indicated for individuals with recurrent thrombosis even in the absence of identifiable primary hypercoagulable states.
-

## **Deep venous thrombosis (D.V.T)**

It means thrombosis of the deep veins commonly of the lower limb

### **Aetiology:**

#### **Virchow's triad:**

**I- Damage of the endothelial** lining of the deep vein ( in sepsis & trauma to the vein)

**II- Venous stasis:** stasis of the blood in the veins occurs in

- 1- Prolonged bed recumbence as in postoperative and in fractures.
- 2- Compression of the veins as by tumour or pregnant uterus
- 3- Congestive heart failure.

**III- Hypercoagulability of the blood**

as in deficiency of antithrombin III & proteins S & C. & Polycythemia.

### **Signs and symptoms**

#### **Symptoms of DVT may include:**

- Edema: Most specific symptom
- Leg pain: Occurs in 50% of patients but is nonspecific
- Tenderness: Occurs in 75% of patients and involves calf muscles or along the course of the deep veins in the medial thigh. Pain and/or tenderness away from these areas is not consistent with venous thrombosis and usually indicates another diagnosis.
- Warmth or erythema of the skin over the area of thrombosis
- Clinical symptoms of pulmonary embolism (PE) as the primary manifestation. occur in 10% of patients with confirmed DVT

N.B.

*As many as 46% of patients with classic symptoms have negative venograms, and as many as 50% of those with image-documented venous thrombosis lack specific symptoms.*

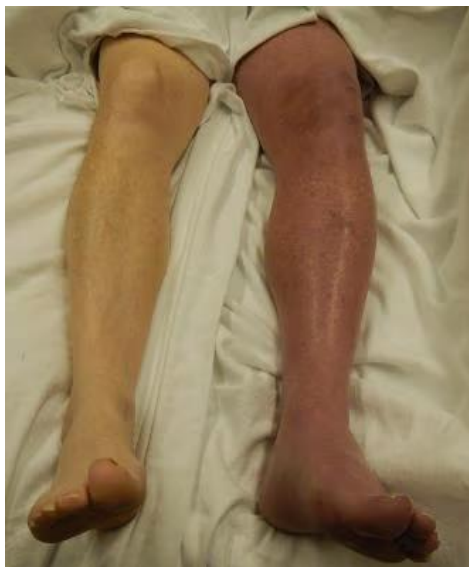### **SIGNS:**

No single physical finding or combination of symptoms and signs is sufficiently accurate to establish the diagnosis of DVT, but physical findings in DVT may include:

- Calf pain on dorsiflexion of the foot with the knee in full extension, the ankle with the knee flexed at 30 degrees (Homans sign) (unreliable due to low specificity)
- A palpable, indurated, cordlike, tender subcutaneous venous segment
- Unilateral lower-extremity edema, erythema, tenderness, or warmth
- Variable discoloration or blanched appearance of the leg due to edema (relatively rare)

**Potential complications of DVT include:**

1. Pulmonary Embolism: As many as 40% of patients have silent PE when symptomatic DVT is diagnosed. More than two thirds of patients with proven PE lack any clinically evident vein thrombosis. Nearly one third of patients with proven PE have no identifiable source of DVT, despite thorough investigations.
2. Recurrent DVT
3. Post-thrombotic syndrome
4. Chronic venous insufficiency
5. **Phlegmasia cerulea dolens:** Patients with venous thrombosis may have variable discoloration of the lower extremity. The most common abnormal color is reddish purple from venous engorgement and obstruction. In rare cases, the leg is cyanotic from massive iliofemoral venous obstruction. This ischemic form of venous occlusion was described as phlegmasia cerulea dolens ("painful blue inflammation"). The leg is usually markedly edematous, painful, and cyanotic. Petechiae are often present.

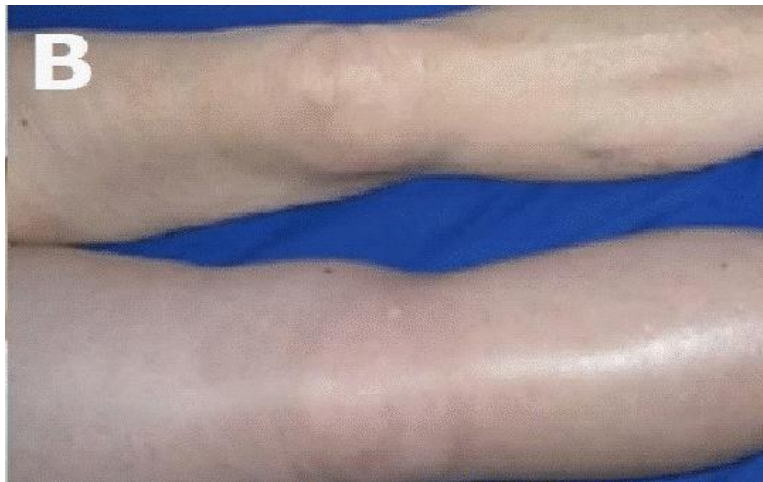

phlegmasia cerulea dolens

**6. Phlegmasia alba dolens:**

- In relatively rare instances, acute extensive occlusion of venous outflow may create a blanched appearance of the leg because of edema.

- The clinical triad of pain, edema, and blanching appearance is termed phlegmasia alba dolens ("painful white inflammation"), a term used to describe massive iliofemoral venous thrombosis and associated arterial spasm.
- This is also known as "milk-leg syndrome" when it is associated with compression of the iliac vein by the gravid uterus.
- The affected extremity is often pale with poor or absent distal pulses. The physical findings may suggest acute arterial occlusion, but the presence of swelling, petechiae, and distended superficial veins suggest severe venous occlusion.
- As many as half of patients with phlegmasia alba dolens have capillary involvement, which poses a risk of damage and irreversible venous gangrene with massive fluid sequestration. In severely affected patients, immediate therapy is necessary to prevent limb loss



phlegmasia alba dolens

### **Diagnosis**

The main laboratory studies to be considered include:

- D-dimer testing: The D-dimer assay has a high sensitivity (up to 97%); however, it has a relatively poor specificity (as low as 35%) and therefore should only be used to rule out DVT, not to confirm the diagnosis of DVT.
- Coagulation studies (eg, prothrombin time and activated partial thromboplastin time) to evaluate for a hypercoagulable state
- In patients with intermediate or high probability of PE, diagnostic imaging studies (eg, ventilation-perfusion scan, multidetector helical CT, and pulmonary angiography) are required

### **Radiological investigations of D.V.T.**

- 1- Duplex U/S scan → the most important test (100% diagnosis).
- 2- Enhanced spiral C.T. → most recent.

### **D.D. of D.V.T (painful limb):**

- 1- Cellulitis → local symptoms & signs of acute inflammation (mention).
- 2- Muscle trauma leads to:
  - a)- Muscle contusion or hematoma.
  - b)- Rupture plantaris tendon.
- 3- Acute ischemia → ( 6 Ps)
- 4- neuralgic pain as in disc prolapse

### **Treatment of D.V.T.**

#### **I- Prevention of D.V.T**

Early ambulation of the patient postoperatively.

- 2- Active limb exercise postoperatively.
- 3- Excess fluid administration → decreases viscosity of the blood.
- 4- Elastic stoking around the calf during surgery → push blood inside the deep veins upwards
- 5- Intraoperative pneumatic calf compression → push blood inside the deep veins upwards

#### **6- Prophylactic heparin in high-risk patients:**

Indications: - history of previous D.V.T – old age – obese – long operations.

Methods:

- Heparin 5000 I u → S.C. 2 hours before surgery then every 12 hours until patient gets out of bed.
- Low molecular weight heparin is better.

#### **II- Active treatment of D.V.T**

- Bed rest and elevation of the limb 45 degree of bed → decrease limb edema and pain.
- Elastic bandage around the limb → helps venous return.
- Anticoagulant therapy:

## A- Heparin

- Mechanism of action:
    - a) increases antithrombin III → ↓ thrombosis.
    - b) Anti IX, X & XI.
  - LMWH: LMWH inhibits factor Xa and minimally affects factor IIa. **Thus a PTT is not used to measure its anticoagulant activity.**
  - Routes of administration:
    - 1- I.V. continuous infusion in glucose 5%
    - 2- S.C. Low molecular weight heparinFor how long? → Till reach double or triple value of INR.
  - Complications of heparin → Bleeding
- Monitoring heparin treatment → APTT (active partial thromboplastin time).

## B- Oral anticoagulant (= Warfarin)

- Mode of action → Anti- VII, IX & X clotting factors
- Route of administration → Oral
- How to monitor? By measuring prothrombin time (PT) and INR  
(INR = PT test/PT normal)
- Started day 2 or 3 from heparin start

## Contraindications to anticoagulation treatment:

- ❖ **Absolute:** include intracranial bleeding; severe active bleeding; recent brain, eye, or spinal cord surgery; pregnancy; and malignant hypertension.
  - ❖ **Relative contraindications:** include recent major surgery, recent cerebrovascular accident, and severe thrombocytopenia
- .....

## Thrombolytic therapy

**Streptokinas** → dissolve the thrombus

## Surgical treatment

1. When systemic thrombolysis is contraindicated owing to a high risk of bleeding, consider surgical thrombectomy or catheter-directed thrombolysis.

2. **IVC filter** → to prevent spread of deep thrombus and occurrence of pulmonary embolism. Used in cases of recurrent shows of pulmonary embolism
- .....

### **Post-Thrombotic Syndrome**

It is the development of symptoms and signs of chronic venous insufficiency following DVT.

#### **Pathophysiology:**

- DVT → long-standing venous hypertension → Damage of the valves → reflux due to valvular incompetence and venous hypertension
- Increased venous pressures are transmitted to the S.C. and dermal capillaries → rupture of some capillaries with hemosiderine deposition → red and bluish discoloration.
- Transudation of fluid and inflammatory mediators in the subcutaneous and dermal tissues, resulting in tissue edema, subcutaneous fibrosis, and, finally, tissue hypoxia and ulceration.

#### **Risk factors:**

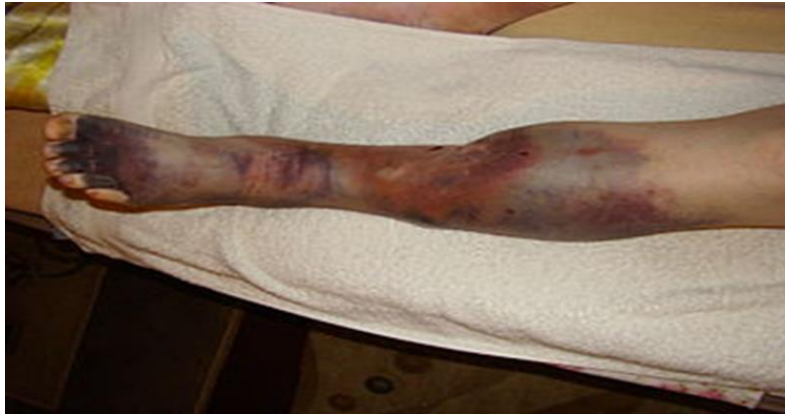- Age > 65
- Proximal DVT
- A second DVT in same leg (recurrent ipsi-lateral DVT)
- Persistent DVT symptoms one month after DVT diagnosis
- Obesity
- Insufficient anticoagulation therapy

#### **Signs and symptoms of PTS:**

- pain (aching or cramping , heaviness)
- Itching and dermatitis
- Edema of the affected area
- varicose veins (secondary)
- Brownish, reddish or bluish skin discoloration

- Thickening of the skin (dermatosclerosis)
- VENOUS ulcer on medial aspect of leg

These symptoms typically are worse after walking or standing for long periods and improve with resting or elevating the leg.



P.T.S

**Investigations:**

**Duplex scan:**

1. State of the deep veins for DVT
2. State of the perforators
3. Secondary varicosities

**Treatment:**

- Leg elevation,
- Compression therapy with elastic stockings, reduce venous hypertension, decrease edema, and improve tissue microcirculation
- Care for leg ulcer : REGULAR dressings + compression stockings
- SURGICAL TREATMENT: Sub-fascial Endoscopic Perforator Surgery (SEPS)

**SEPS** is a minimally invasive surgical technique used to treat:

- 1 - V.V.
- 2 - Post-thrombotic syndrome
- 3 - Chronic venous ulcers caused by damaged perforating veins due to deep vein thrombosis

**In PTS:** symptoms and trophic lesions are markedly decreased and a dramatic reduction in the ulceration rate is achieved with SEPS.

---

## **Drugs used in blood disorders (Pharmacology department)**

### **Anticoagulants**

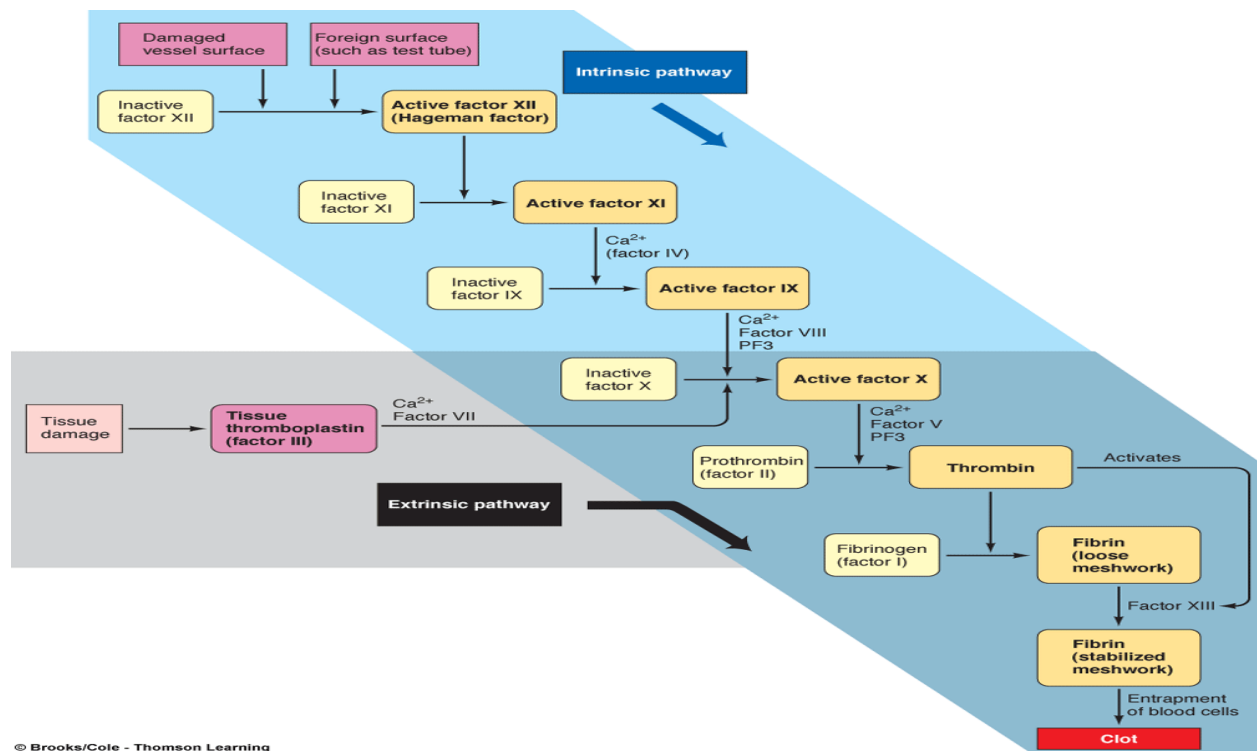
Anticoagulants inhibit blood coagulation cascade and are used in prophylaxis and treatment of thrombi-embolic disorders.

#### II. Ant platelet drugs

They interfere with platelet function preventing thrombus formation.

#### III. Fibrinolytic drugs

Fibrinolytic cause lyses of the already formed thrombi or emboli.



## ANTICOAGULANTS

### CLASSIFICATION:

1-substances which interfere with ionized  $Ca^{++}$  (in vitro only)

a) Precipitation of calcium by  $Na^+$  or  $K^+$  oxalates. It is used in blood samples.

b) Diminished ionized calcium by  $Na^+$  or  $K^+$  citrate or by Tetrasodium Edetate. It is used in blood samples and blood banks

2-Direct acting; Heparin which is effective in vivo, and vitro, rapid onset, short duration

3-Indirect acting: oral anticoagulants.

a) Coumarins Dicoumarol, Biscoumacetate (tremexan), warfarin, Cyclocoumarol.

b) Indandione: phenindione (Dindivan) - Divenandione

### Comparison between Heparin and Warfarin

	<i>Heparin</i>	<i>Warfarin</i>
<i>1-source</i>	<i>-animal origin -Natural found with histamine in mast cells in liver and lung</i>	<i>-plant origin -synthetic</i>
<i>2-Chemistry</i>	<i>Sulfated mucopolysaccharides Strongly acidic with strong electro -ve charge, combine with +ve charges of blood coagulation factors.</i>	<i>Coumarine derivatives</i>
<i>3-absorption and fate</i>	<i>-parentally (iv, sc) -not pass BBB or placenta -metabolized in liver and tissues (by heparinase enzyme) -excretion in urine (20% as such) -end product uroheparin (80%)</i>	<i>-given orally, bound to plasma proteins -pass BBB &amp; placental barrier (teratogenic) -metabolized slowly in liver</i>

4-actions	1-anticoagulant in vivo and in vitro a)potentiate action of antithrombin III b)increase heparin cofactor-II c)direct anti-thrombin 2-inhibits platelet aggregation 3-lipemic clearing action due to activation of lipoprotein lipase enzyme	Anticoagulant in vivo only, competes with vitamin k in liver for synthesis of coagulation factor prothrombinII, VII, IX, X
5-onset and duration	Immediate onset after IV and Duration for 4 hours	-delayed onset 1-2 days and Duration for 2-3 days
6-dose	IV or infusion 5000 U/4 hr Heparin Sc(Miniheparin):5000u/8hr	Initially 10mg for 2 days Maintenance ;2-10mg
7-control of dose	-coagulation time(normally 5-7 min). -partial thromboplastin time(pTT)(26-28 sec).	-prothrompin time prolonged (normally 12-15 sec) -pT expressed as IN R -INR(international normalized ratio) should be 3 times normal

8-therapeutic uses	<p><u>1-treatment of thromboembolic disease</u>  -cns:cerebral thrombosis  -cvs:M.infarction,unstable angina after angioplasty and stent  -pulmonary embolism  e.g. deep venous thrombosis  <u>2-prophylactic to thromboembolic complication of surgery</u></p>	<p>1-treatment of thromboembolic diseases e.g. thrombosis  2-prophylactic to thromboembolic complications of surgery.</p>
9-side effects	<p>1-Hemorrhage  2-Hypersensitivity  3- K(potassium)  4-Transient alopecia  5-Thrombocytopenia  6-Osteoporosis and fracture</p>	<p>1-Bleeding especially in liver diseases.  Sudden withdrawal  Thromboembolic  2-Allergy  3-G.I.T upset: anorexia,vomiting.</p>
<b>10-contraindication</b>		<p>1-CNS:IC hemorrhage, brain injury, spinal, eye surgery, lumbar puncture  2-CVS:subacute bacterial endocarditis,severe hypertension.  3-Active TB  4-peptic ulcer  5-Threatened abortion  6-Bleeding tendency:hemophilia,purpura.  7-Allergy.</p>

<b>11-Antidote</b>		1-Protamine sulphate IV 1 mg 1- Vitamin K 2-fresh bl. transfusion For each 100 U.heparin. 2-Fresh blood transfusion.
--------------------	--	--

## **HEPARIN DERIVATIVES**

### **HIGH MOLECULAR WEIGHT HEPARIN**

HMW fraction of heparin from 5000-30000 Dalton)

Have high affinity for antithrombin III markedly inhibit blood coagulation

Require carefull control of PTT

### **LOW MOLECULAR WEIGHT HEPARIN**

LMW fraction of heparin (8000 Dalton)e.g Enoxaparin,Daltaparin,and Rivaparin.

Inhibit activated factor X and have less effect on antithrombin and Coagulation in general.

#### **Advantages:**

- A) Minimal bleeding tendency
- B) Easy calculation of dose
- C)Long T<sup>1/2</sup> SC or IV

## **Direct thrombin inhibitors**

### **Lepirudin**

- It is irreversible thrombin inhibitor.
- Recombinant derivative of Hirudin and Danaparoid-Non Heparin glycosaminoglycans isolated from porcine intestinal mucosa.
- Both are used IV for patients with heparin induced thrombocytopenia

### **Bivalirudin**

- Administered intravenously
- Inhibits activation with rapid onset
- Used in percutaneous coronary angioplasty

### **Argatroban**

- Is a small molecule thrombin inhibitor
- Used in ; patients with heparin induced thrombocytopenia with or without thrombosis and coronary angioplasty
- It is given by IV infusion

## **New oral anticoagulants:**

- Dabigatran (Pradax) is a new oral anticoagulant acting as direct thrombin inhibitor.

- It produces the same anticoagulant effect of warfarin but with less hemorrhagic complications.

### **Drug Interaction of Oral anticoagulant**

#### **A-Increased anticoagulant effect:**

- 1-broad spectrum antibiotic as tetracycline → inhibit synthesis of vitamin K.
- 2-Liquied paraffin → inhibit absorption of vitamin K.
- 3-phenylbutazone ,indomethacin,clofibrate → displace oral anticoagulant from plasma protein binding sites.
- 4-enzymes inhibitors as Cimitedine,Allopurinol,Chloramphenicol.
- 5-Aspirin large dose Synergist effect.
- 6-liver disease and hyperthyroidism.

#### **B-Decreased Anticoagulant Effect:**

- 1-Cholestyramine → decrease absorption and bioavailability
- 2-Barbiturates,Rifampicin → Enzyme induction
- 3-Estrogen → increased clotting factors
- 4-Hypothyrodism

### **Antithrombotic**

- 1-Aspirin: inhibits thromboxan A2 synthetase enzyme,"in small dose"(75-150mg)
- 2-Dipyridamol(persantin):
  - Phosphodiesterase inhibitors cAMP in the platelet
  - Enhances prostacyclin
- 3-Teclopidine-Clopidogrel:
  - inhibits transformation of glycoprotein (GIIb/IIIa) into active metabolite
  - may used in post MI and unstable angina
- 4-Abciximab-Tirofiban-Eptifibatide-Integrelin
  - Blockers of platelet membrane receptor(GP IIb/IIIa)
  - Monoclonal antibodies against GP receptors given IV during intervention
  - Used in acute coronary syndrome and postangioplasty
- 5-Sulphinopyrazone(Anturan):cycloxygenase inhibitor
- 6-Dextran-Heparin-Pentoxifylline-Nifedipine-Clofibrate(atromid S)
- 7-Prostacyclin PGI<sub>2</sub>(Epoprostanol):short duration(minutes)

### **Control of thromboembolic disorders**

- 1-Anticoagulants (to prevent extension of thrombus)
- 2-Inhibitors of platelet aggregation(to prevent formation of further thrombi)

3-Thromboembolic and fibrinolytics (to dissolve thrombus)

**THROMBOLYTICS AND FIBRINOLYTICS**

Agent used to lyse recently formed thrombi injected IV ,intra-arterial or intracoronary

**I-STREPTOKINASE:**

- a) Obtained from hemolytic streptokinase - antigenic
- b) Combines with Pro-activator complex - activation of plasminogen
- c) 1.5 Million units in 200 ml saline IV.infusion, single dose
- d) Anistreplase plasminogen-streptokinase complex

**II-UROKINASE:**

-Obtained from human urine not antigenic. Direct activator of plasminogen

**III-Tissue Plasminogen Activator (TPA,Alteplase, Actilyse)**

- a) Prepared by recombinant DNA technology Not antigenic but expensive
- b) Selective activation of plasminogen bound to fibrin and not circulating plasminogen more effective.No systemic fibrinolysines and rapid acting
- c) 10mg IV bolus then 50 mg over an hour then 40 mg over 2 hours

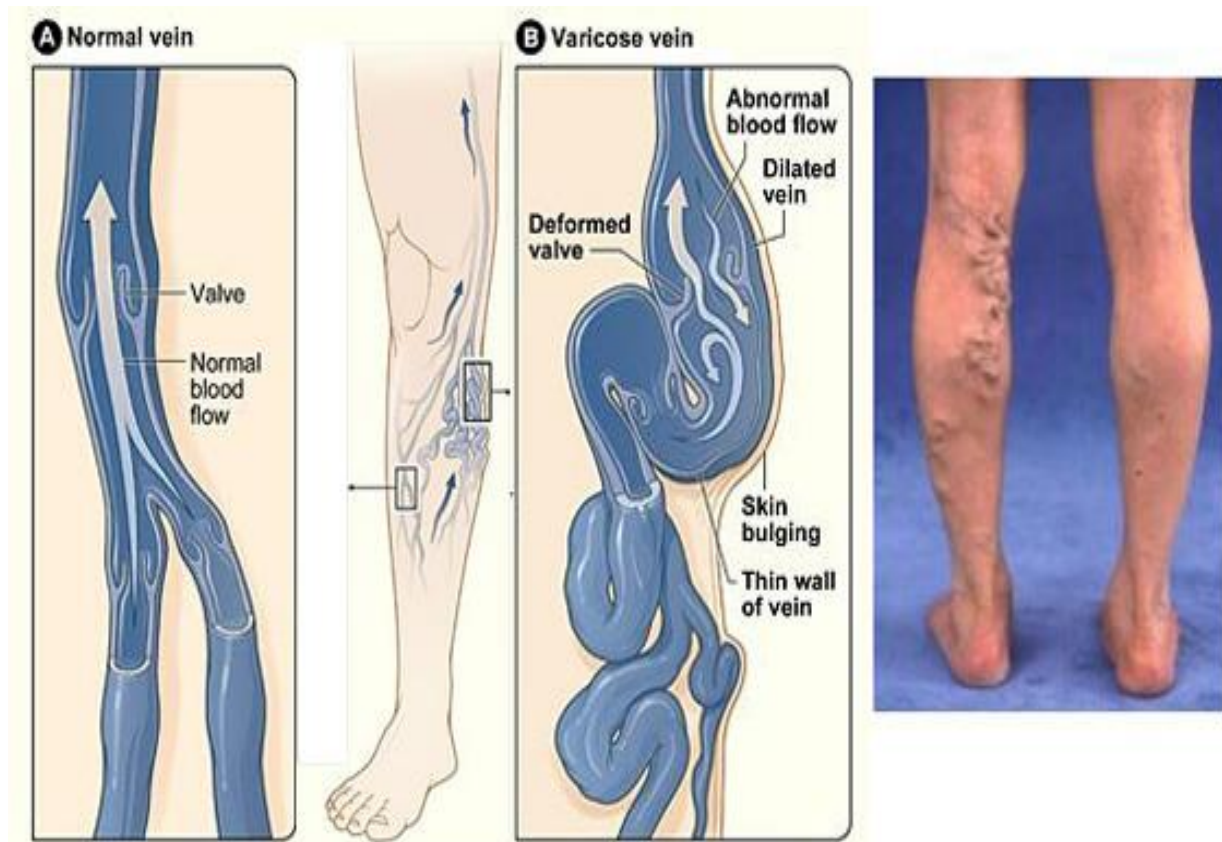
**Antifibrinolytics**

Aminocaproic acid and Transexaminic acid

- Competitive antagonists of fibrinolytics activator
- Used to treat hemorrhage due to large doses of thrombolytics

.....

## Varicose veins



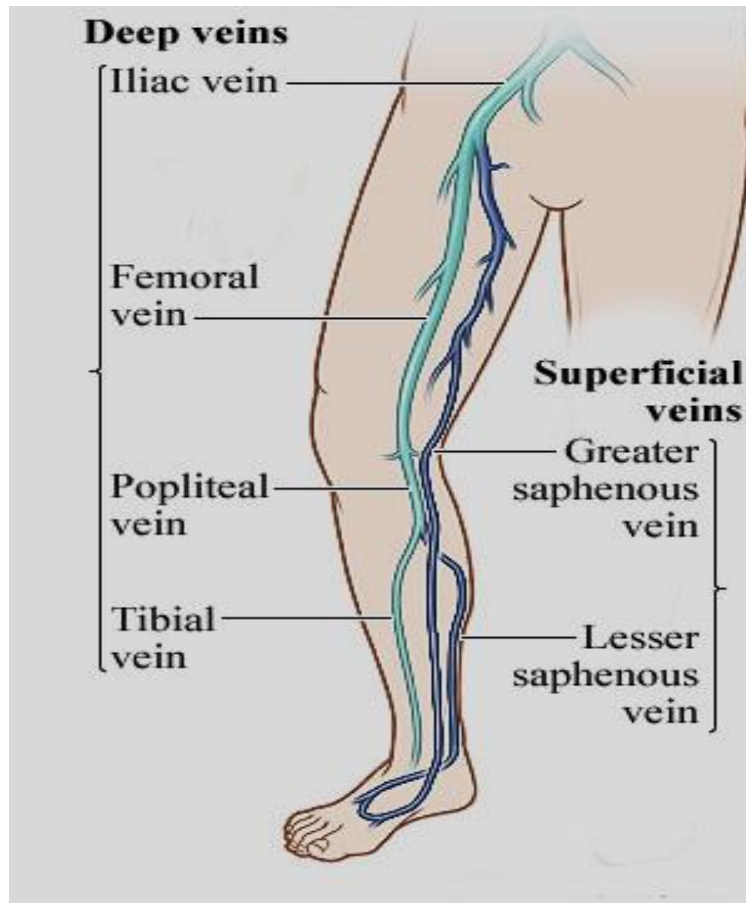
### ***What are varicose veins?***

- When the vein becomes dilated, tortuous and elongated then it is called varicose vein.
- Varicose veins are defined as subcutaneous veins which appears dilated and tortuous.

### **What is the superficial venous system of the L.L.?**

- These are the veins present superficial to the deep fascia (S.C.)
- **Long saphenous vein:**
  - starts from medial aspect of dorsal venous arch of foot
  - ascends upwards anterior to the medial malleolus , along medial border of tibia and patella, then along medial aspect of thigh

- Pierces the deep fascia at the saphenous opening to join the common femoral vein (SFJ) 3.5 cm below and lateral to the pubic tubercle.
- The saphenous nerve is closely related to the long saphenous V. in the leg
- **Short saphenous vein:**
  - **Starts** at the lateral side of dorsal venous arch
  - **Ascends** behind the lateral malleolus
  - Then along the posterior aspect of leg
  - It pierces the deep fascia to join the popliteal vein anywhere from mid-leg to popliteal fossa
  - Closely related to sural nerve.
- **Perforating veins:**
  - These veins present in the leg directly drain skin of this area to the deep veins
  - Present 2, 4, 6, inches above the ankle
  - Site for post-thrombotic syndrome
- **Communicating veins:**
  - **These** are connecting veins that join the superficial veins with the deep veins
  - Direct blood from superficial to deep



***What do you mean by primary varicose vein?***

- In this no obvious cause could be found to explain the varicosity
- Weakness in vein wall or valve failure has been responsible
- A congenital predisposition with occupational influence leads to development of primary varicose vein (long standing jobs).

***What is secondary varicose vein?***

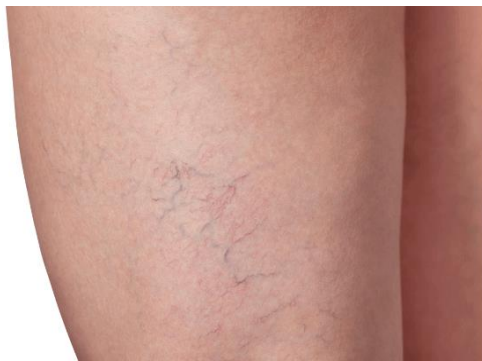When varicose vein occurs due to some cause:

1. **Deep venous thrombosis**—leading to increased pressure in superficial vein—lead to valvular damage and formation of varicosity in the superficial veins
2. **Arteriovenous fistula**—arterializations of veins occur due to increased pressure in the veins leading to venous varicosity

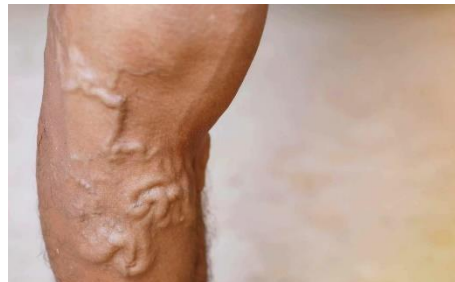3. *Obstruction to deep vein by a **pelvic mass*** may lead to superficial varicosity due to occlusion of the deep veins
4. **Pregnancy**—compression of the pelvic veins as well as hormonal effects of estrogen and progesterone which causes the smooth muscles in the vein wall to relax
5. **Inferior vena cava (IVC) thrombosis.**

***What are the clinical stages of patient with varicose veins?***

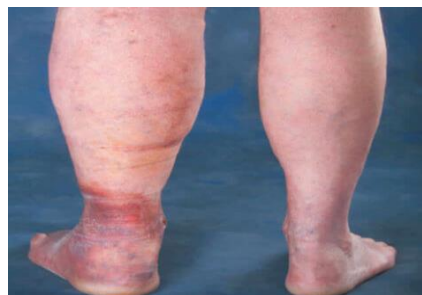***Stage 1: Telangiectasia***



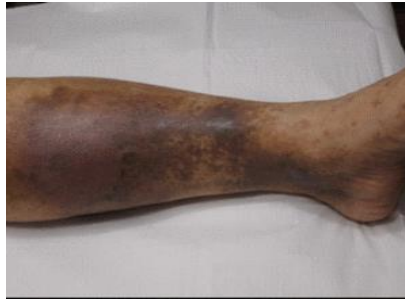***Stage 2 = varicose veins:***



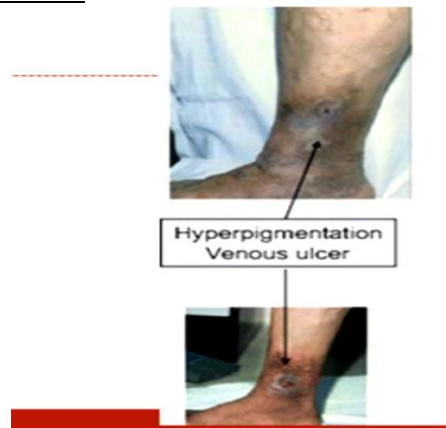
***Stage 3: Marked edema (C.V.I)***



***Stage 4= Dermatosclerosis (PTS):***

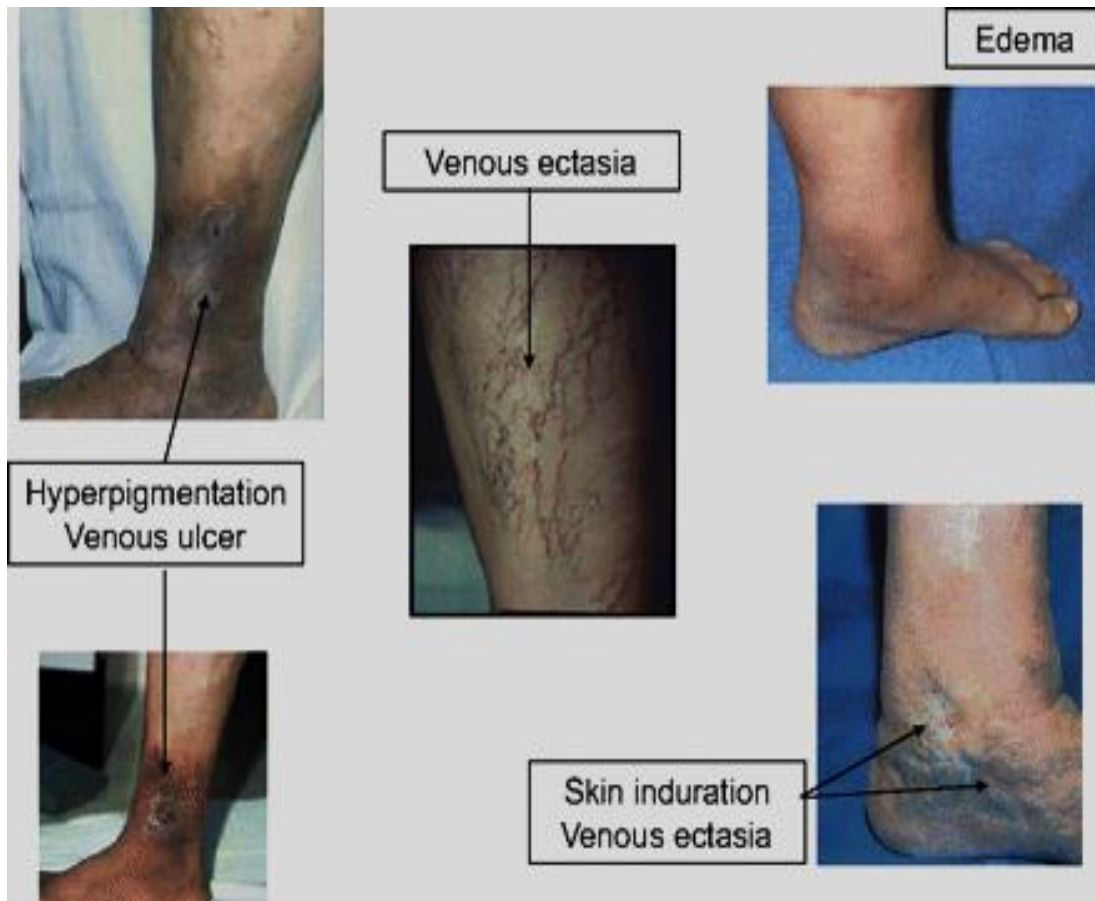

**Stage 5: active venous ulcer:**



**Clinical presentations of varicose veins:**

- pain in the legs more towards the evening and on prolonged standing
- Swelling around the ankle more towards the evening (edema)
- Skin pigmentation: more with secondary V.V
- Eczema → secondary V.V
- Venous ulcer→ secondary V.V.
- Cosmetic due to dilated veins in the legs. (long vs. short saphenous v.)



Secondary V.V. + P.T.S

**Mention differences between primary and secondary V.V.**

**1. Etiology.**

**2. Pain:**

- mild or absent in primary
- Marked in secondary

**3. Distribution:**

- Primary: Long or short saphenous V.
- Secondary: irregular , no specific pattern + dilated crossing veins at the groin (superficial circumflex iliac – superficial epigastric – superficial external pudendal)

**4. Presence of complications:**

- Primary: minimal or absent
- Secondary: edema, pigmentation, eczema, ulceration,.

(post-thrombotic syndrome)

***What are the complications of varicose veins?***

- Superficial thrombophlebitis.
- Hemorrhage from minor trauma. To control severe hemorrhage—rest with foot end elevation and compression bandaging
- Skin pigmentation and eczema more with 2ry V.V.
- Varicose ulcer. 2ry V.V

***How will you do inspection?***

- 1- In inspection ascertain which systems of veins are affected by varicosity.
- 2- Look at the leg from front, back and the side to ascertain which veins are affected by varicosity
  - Long saphenous V. in the medial aspect of the leg and thigh
  - Short saphenous V. in the posterior aspect of the leg
  - Blow outs: punches of veins at sites of facial defects.
- 3- Look at signs of post-thrombotic syndrome as ulcer, eczema,....

***How will you do Trendelenburg's test?***

***Used to detect incompetence SFJ, or communicator valves***

1. Patient is asked to lie down and the superficial veins are emptied by elevating and milking the leg.
2. The tourniquet is tied below the saphenous opening and the patient is asked to stand.
3. The tourniquet is kept tied for 2 minutes and the condition of the superficial veins are observed, then the tourniquet is released and look for filling from above.
  - If the veins start getting dilated with the tourniquet kept tied below the saphenous opening, this suggests there is **perforator incompetence below the sapheno-femoral junction.**
  - Release the tourniquet. If there is further filling from above, this suggests there is also **incompetence of sapheno-femoral junction.**
  - If on releasing the tourniquet there is no further filling from above, means competent SFJ.
  - If keeping the tourniquet tied, there is no filling of veins from below then **this means that there is no incompetent perforators**

- If on releasing the tourniquet there is filling from above → means incompetent only SFJ.

### **What is multiple tourniquet test?**

- **Aim:** to locate the site of incompetent communicators when the trendelenberg's test shows filling from below
- After limb elevation to empty the veins one tourniquet applied below SFJ , 2<sup>nd</sup> above knee and 3<sup>rd</sup> one below knee
- Release tourniquet from below upwards in sequences and observe the filling of veins.

### **How will you find the saphenofemoral junction?**

- The saphenofemoral junction (termination of great saphenous vein into the femoral vein) lies at the saphenous opening which is situated 3.5 cm below and lateral to the pubic tubercle.
- Mark the pubic tubercle and measure 3.5 below the pubic tubercle and 3.5 cm lateral to it.

### **What is saphena varix?**

- It is the dilated terminal end of the great saphenous vein where a thrill may be palpable.
- A cough impulse may be palpable over the saphena varix due to incompetence of valve at the saphenofemoral junction.

### **How will you do Schwartz test?**

1. The patient is asked to stand. Keep one finger at the saphenous opening and tap the dilated vein lower down in the leg.
2. The test is said to be positive when an impulse is palpable at the saphenous opening on tapping the vein at the lower level.
3. Positive Schwartz test is found in gross varicosity of the veins

### **How will you do modified Perthes' test?**

- **Aim :** detect patency of deep system
- A tourniquet is tied below the saphenous opening with the veins being full. Ask the patient to walk for about 3–5 minutes

- If the deep veins are patent, the dilated superficial veins will collapse. However, if the deep veins are occluded by thrombosis then the superficial veins will become more distended and patient will complain of bursting pain in the leg. This is said positive Perthes' test. This suggests an occluded deep venous system due to previous deep venous thrombosis.

***How will you investigate varicose patient?***

**1- Duplex scan of the venous system of the lower limb.**

- The anatomical delineation of the deep vein and the patency of the deep veins may be assessed.
- The normal deep veins are compressible. If the deep veins are occluded by thrombus, the vein is not compressible. The thrombus in the deep vein may be seen.
- The venous reflux may be demonstrated.
- the competent valves show no reverse flow but the incompetent valve allows reverse flow
- The functional assessment and the site of reflux may be precisely localized.
- Sapheno-femoral,sapheno-popliteal reflux and reflux at the sites of other perforators may be demonstrated.

***How will you treat primary V.V.?***

**I- Conservative:** by veno-tonic drugs and elastic stockings – avoid P.F. as prolonged standing

**II- SCLERO-THERAPY:**

- 1) In small localized varicosities - Recurrent after surgery
- 2) Using ethanol-amine oleate injection into an empty dilated vein followed by compression of the vein walls
- 3) Side effects: extravasation and bad results - DVT

**III- surgical treatment:**

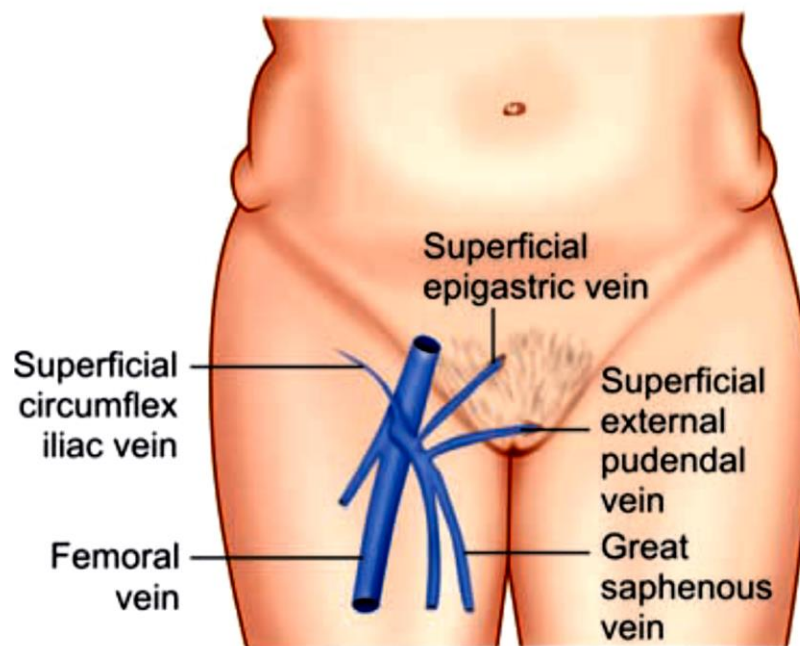
- Sapheno-femoral **flush** ligation and disconnection, (**Trendlenberg's operation**)

- **Sapheno-pop.** disconnection in varicosities of short S.V.
- Stripping of great saphenous vein up to the upper calf and ligation of perforators above the ankle.

**IV- Treatment of 2 ry V.V.** → Mainly conservative by compression stockings

***What will happen if you ligate the great saphenous vein little away from the sapheno-femoral junction?***

- The ideal procedure is flush saphenofemoral ligation, that is ligation of the great saphenous vein at its junction with the femoral vein.
- All the tributaries—superficial circumflex iliac veins, superficial epigastric veins and the superficial external pudendal veins need to be ligated separately.
- If the saphenous vein is ligated little away from the junction keeping a stump of great saphenous vein then this segment of vein will continue to get dilated forming a **saphena varix** as the incompetent valve at sapheno-femoral junction remained and all the tributaries will also get dilated.



## Tributaries of long saphenous V.

### ***Why the whole length of great saphenous vein is not stripped?***

- The saphenous nerve lies in close contact with the great saphenous vein in the leg.
- So stripping of great saphenous vein in the leg may cause injury to the saphenous nerve.
- If individual incompetent perforators below the knee are ligated, this varicosity will disappear. So stripping of great saphenous vein in the leg is not required.

### ***What is Trendelenburg's operation?***

- Trendelenburg's operation involves flush ligation of sapheno-femoral junction.
- An oblique incision is made over the groin below the inguinal ligament starting at the level of femoral artery and extending medially for 4 cm.
- The long saphenous vein, the superficial femoral vein and common femoral vein is exposed by dissection.
- The tributaries of the saphenous vein superficial circumflex iliac, superficial epigastric and the superficial external pudendal veins are dissected and ligated individually.
- The great saphenous vein is ligated and divided flush with the femoral vein

### ***How will you treat the varicosity affecting the short saphenous system of vein?***

- The treatment involves flush ligation of the sapheno-popliteal junction and stripping of the dilated segment of the short saphenous vein.
- The termination of the short saphenous vein is highly variable and ends at the popliteal vein at a variable point from 2 cm below the knee up to 15 cm above the knee joint line.
- The short saphenous vein is ligated flush with the popliteal vein.
- A metal stripper is inserted through the upper end of the divided short saphenous vein and retrieved at the lower end of the vein.

- A suture is used to attach the vein to the upper end of the stripper and the vein is stripped by pulling the stripper from below.

***What is the postoperative management following varicose vein surgery?***

- Compression bandage is applied at the end of surgery to prevent bleeding and bruising.
- The compression bandage is kept for 2 days and then replaced with an elastic stocking which is kept for about 7 days.

***What are the complications following varicose vein surgery?***

- Bruising, bleeding and hematoma
- Injury to saphenous or sural nerve.
- Venous thrombosis in residual varicose vein
- Deep venous thrombosis.

***How will you manage small residual varicosities following surgery?***

The residual minor varicosities following surgical treatment may be managed either by compression bandage or injection sclerotherapy.

***What is the role of conservative treatment for varicose veins?***

- Secondary varicose veins: Surgery is contraindicated in patient with varicose vein secondary to deep vein thrombosis as these are the only channels for venous drainage from the lower limbs
- Patient unfit for surgery
- Patient refusing surgical treatment

Graduated compression stockings are useful for varicose veins. The ankle compression pressure of 35–40 mm Hg is ideal.

***What are the recent advances in treatment of varicose veins?***

There has been newer and less invasive treatment of varicose veins which includes:

1. Radiofrequency ablation of varicose veins (RFA)
2. Endovenous laser ablation of varicose veins (EVLA)

***What are the indications of injection sclerotherapy?***

- Minor varicosities where the main trunks of great and short saphenous system

are normal

- Residual varicosities following surgery.

### ***How does sclerotherapy cure varicose veins?***

- The sclerosant solution injected into the vein destroys the endothelial lining and results in fibrotic occlusion of the vein.
- To be effective the sclerosant solution has to be injected into the empty vein. The vein is then compressed so that the two walls remain in contact so that no thrombus is formed within the vein. The idea is to produce sclerosis and fibrotic occlusion of the vein so that no recanalization occurs.

### ***What are the complications of sclerotherapy?***

- Skin pigmentation
- Ulceration of the skin if injected in extravascular
- superficial thrombophlebitis
- Deep venous thrombosis.

### ***What is SEPS for treatment of varicose veins?***

- This is a minimally invasive surgery for varicose vein. SEPS stands for subfascial endoscopic perforator surgery.
- The perforators are localized by preoperative duplex scanning and marked on the skin surface.
- Through a small incision the videoendoscope is introduced into the subfascial plane. Through additional 5 mm ports using endodissector, the perforators are dissected, ligated and divided under vision.
- This technique is used increasingly and has shown good results.

### ***What are the characteristics of varicose ulcer?***

1. Venous ulcer is one of the important causes of leg ulcer.
2. Venous ulcer is commonly situated just proximal to the medial or lateral malleolus but may extend to the ankle

3. Varicose veins are present and there is associated lipo-dermato-sclerosis and pigmentation in the skin due to hemosiderosis.
4. No associated arterial diseases as the peripheral pulses are normal.

***What are the other causes of leg ulcers?***

1. Ischemic ulcer (dorsum and tips of toes)
2. Diabetes ulcer (infective ulcer) usually sole of foot - anywhere
3. Neuropathic (sole of foot) + neuropathy
4. Trauma + history of trauma
5. Malignant ulcer—squamous cell carcinoma (raised, everted edge, hard base & necrotic floor)
6. Autoimmune diseases— (SLE).

***How does venous ulcer develop?***

- Due to incompetence of valves in the superficial or deep veins, there is reverse flow in superficial or deep veins. This is more marked during standing or walking and results in ambulatory venous hypertension.
- This venous hypertension is reflected on to the microcirculation.
- The capillaries in the skin enlarge in size and Because of the increased pressure in the capillaries, there is extravasation of blood elements from the capillaries.
- A perivascular cuff of fibrin, acts as a barrier to diffusion, preventing nutrient exchange between the capillaries and the tissues resulting in tissue damage and ulceration.
- Also a release the proteolytic enzymes, oxygen free radicals cause damage to the capillary endothelium and thrombosis in microcirculation and cause tissue damage resulting in skin ulceration.

***How will you manage venous ulcer?***

1. In patients where the varicose ulcer is due to superficial varicosity, the ulcer heals well with surgical treatment of varicose veins.
2. But varicose ulcer due to associated deep venous thrombosis, conservative treatment of ulcer is the answer Or SEPS.

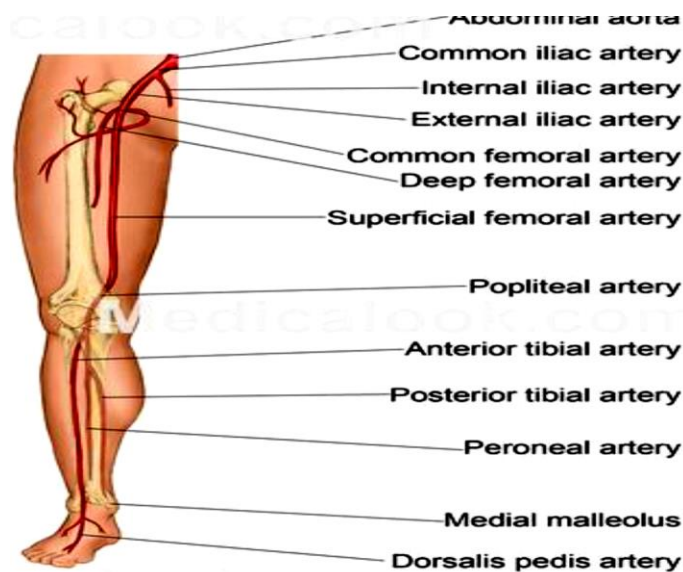
***What is the conservative treatment for varicose ulcer?***

- Local cleaning of the ulcer and dressing.
- A pressure of 30–45 mm Hg applied at the ulcer site may fasten healing. Below knee stockings are effective in healing of venous ulcer.
- **Compression** helps venous drainage and prevents stasis

***How will you treat varicose vein secondary to deep venous thrombosis?***

- In post deep venous thrombosis varicose vein the superficial vein are the only channels for return of lower limbs blood to the heart. Stripping and ligation of varicose vein in this situation is contraindicated.
  - The conservative treatment for varicose vein is required in this situation—rest with foot elevated/ use of elastic stocking
- .....

**Arterial surgery**



**Topics:**

- 1- Acute Ischemia
- 2- Chronic Ischemia
- 3- Aneurysms

- 4- A-V shunt
- 5- Diabetic Foot and Gangrene

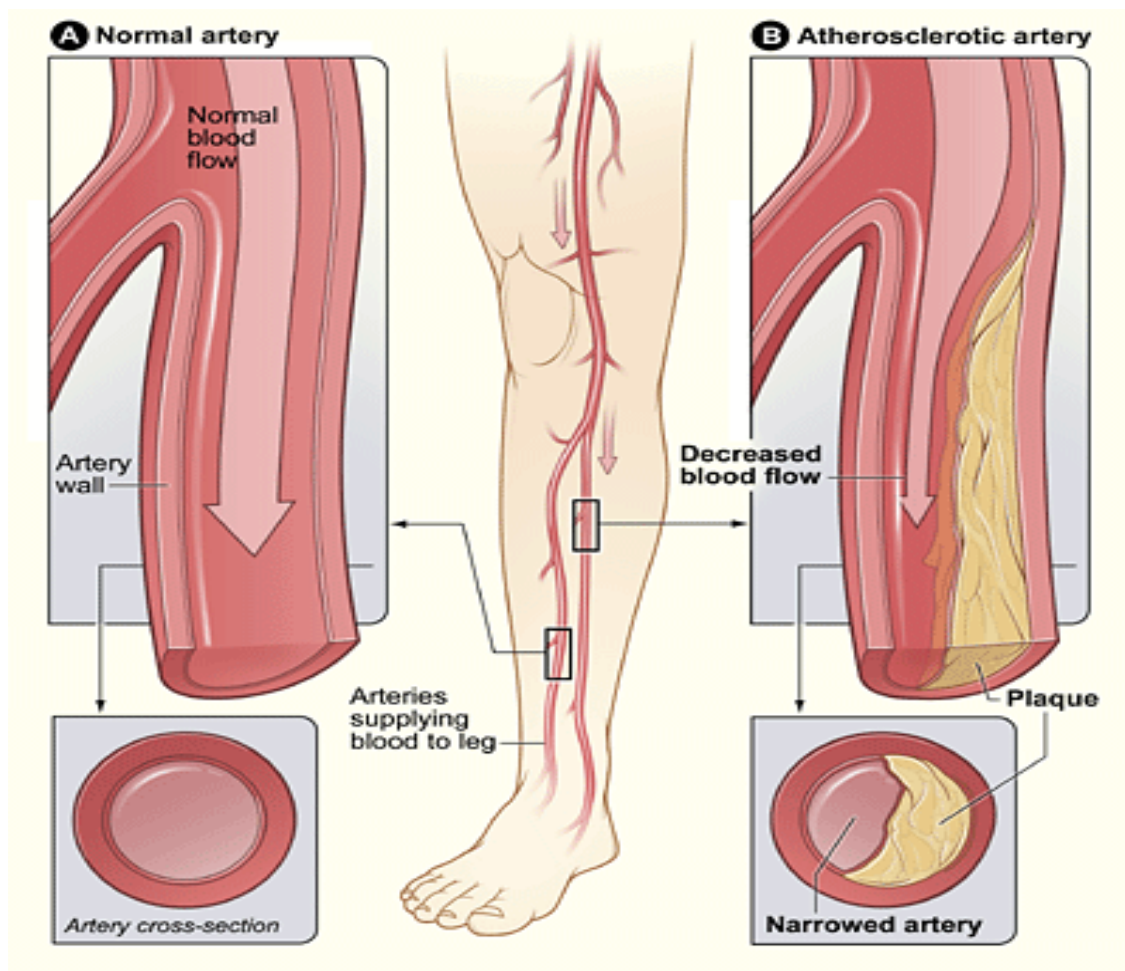
---

### ACUTE ISCHEMIA

**Definition:** It means sudden interference with the arterial blood supply of limb or organ.

**Aetiology:**

1. **Arterial embolism** → (most important cause).
2. Acute arterial thrombosis → usually on top of atherosclerosis,
3. Arterial aneurysm
4. Arterial injuries (transection – compression – hematoma – thrombosis).
5. Extensive ilio-femoral DVT → Reflex arterial spasm.



Effect of atherosclerosis

Clinical features	Embolus	Thrombosis
<b>Severity</b>	Complete ischaemia (no collaterals)	Incomplete ischaemia (collaterals)
<b>Onset</b>	Seconds or minutes	Hours or days
<b>Limb</b>	Leg 3:1 arm	Leg 10:1 arm
<b>Multiple sites</b>	Up to 15%	Rare
<b>Embolic source</b>	Present (usually AF)	Absent
<b>Previous claudication</b>	Absent	Present
<b>Palpation of artery</b>	Soft; tender	Hard/calcified
<b>Bruits</b>	Absent	Present
<b>Contralateral leg pulses</b>	Present	Absent
<b>Diagnosis</b>	Clinical	Angiography
<b>Management</b>	Embolectomy, warfarin	Medical, bypass, thrombolysis
<b>Prognosis</b>	Loss of life > loss of limb	Loss of limb > loss of life

*Differences between embolic and thrombotic causes*

### Arterial embolism

#### Causes:

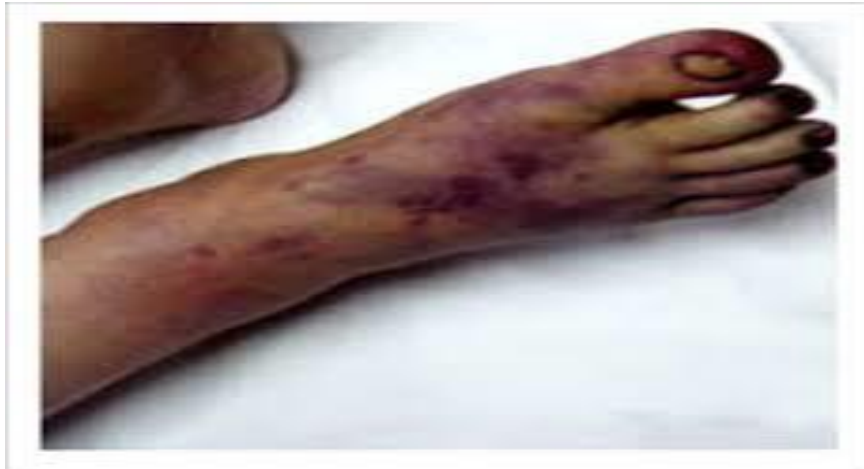- A) Detached embolus from the left side of the heart:
- i) Atrial fibrillation (AF).
  - ii) Infective endocarditis.
  - iii) Myocardial infarction, (mural thrombus).
  - iv) Mitral stenosis
- B) Detached embolus from proximal artery having thrombus as in atherosclerosis or aneurysm.

#### Sites of arrest of emboli:

- 1- Lower limb → Bifurcation of common femoral a.  
→ Bifurcation of popliteal a.
- 2- Bifurcation of abdominal aorta.  
***Both 1 & 2 produce acute ischemia of lower limb***
- 3- Bifurcation of brachial a. → acute ischemia of upper limb
- 4- Bifurcation of common carotid a. → cerebral stroke.

### **Pathophysiology:**

- Acute arterial occlusion is associated with intense spasm in the distal arterial tree, the limb will appear white..
- Over the next few hours, the spasm relaxes and the skin fills with deoxygenated blood leading to mottling that is light blue or purple, has a fine reticular pattern, and blanches on pressure.
- Stagnant blood coagulates leading to mottling that is darker in colour, coarser in pattern, and does not blanch.
- Finally, large patches of fixed staining black progress to blistering and liquefaction



**Acute ischemia**

### **Clinical picture:**

#### **I- Acute embolic ischemia of lower limb:**

##### **A- General symptoms**

- History of cardiac problems → AF – infarction – endocarditis

##### **B- General signs → irregular tachycardia (AF).**

##### **C- Typical Local symptoms & signs of acute ischemia:(6 Ps):**

- i) Pain → severe and of sudden onset and progressive.
- ii) Pallor
- iii) Paralysis or paresis
- iv) Progressive coldness of the limb distal to site of occlusion.
- v) Parasthesia → abnormal sensation (tingling).
- vi) anaesthesia: alarming sign: indicating nerve ischemia and damage

- The condition started by sudden onset of severe lower limb pain and the leg becomes white.
- **After 6 – 12 hours** → capillary dilatation occurs & become filled with deoxygenated blood → mottling of the skin → followed by bluish discoloration of the skin (fixed color changes)

## **II- Clinical picture of acute thrombotic ischemia**

The same as acute embolic ischemia **Except that:**

1. Cardiological problems is not common etiological factors.
2. Old age (astherosclerotic)
3. History of recent trauma with arterial contusion with thrombosis
4. Associated manifestations of chronic ischemia in the same limb, (e.g. trophic changes & intermittent claudications) in astherosclerotic cases
5. Gradual onset of acute ischemia manifestations over hours or days –

## **Complications of acute ischemia:**

### **A. Compartmental syndrome:**

- The ischemic muscles become swollen → oedema → more compression on the vessels → more ischemia → on revascularization more oedema occurs → more compression. Patient needs fasciotomy to relieve the compression.

**B. Wet type of gangrene** in neglected cases more than 6-12 hours.

**C. Acute DVT:** due to blood stagnation in the deep veins.


## **How to manage acute ischemia of the lower limb?**

**Depending on the clinical presentation:**

## Clinical classification of acute limb ischemia

**Table 4. Clinical Categories of Acute Limb Ischemia**

Grade	Category	Sensory Loss	Motor Deficit	Prognosis
I	Viable	None	None	No immediate threat
IIA	Marginally threatened	None or minimal (toes)	None	Salvageable if promptly treated
IIB	Immediately threatened	More than toes	Mild/moderate	Salvageable if promptly revascularized
III	Irreversible	Profound, anesthetic	Profound, paralysis (rigor)	Major tissue loss Amputation Permanent nerve damage inevitable

  
**The diagnosis approach depend on the availability of imaging modality and the time required to perform which should be weighed against the urgency for treatment and that determined by clinical classification**

### **Investigations:**

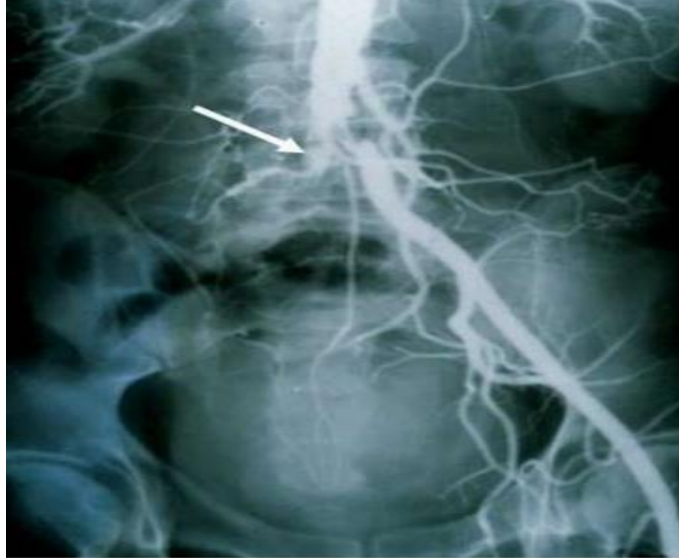**1- Duplex scan:** done urgently on the vessels of the affected limb.

- In acute embolic occlusion,  $\geq 0.5$  mm dilatation in the diameter of occluded artery
- in acute thrombotic occlusion, diminution in the occluded artery diameter
- Cut off flow (no distal blood flow)
- state of the arterial wall (normal or atherosclerotic)

**2- Angiography:**

- demonstrates the site of occlusion
- determine the state of collaterals (run off)
- determine state of the occluded vessel (normal or atherosclerotic)

**3- Echocardiography:** to detect lesions and arrhythmias of the heart.



Acute ischemia

**Treatment of acute ischemia:**

**I- Embolic type:**

**a) Analgesics for pain up to Morphine.**

**b) I.V. heparin 5000 IU / 2 hours**, guided by PTT done every 12 hours and should be kept 2 : 3 times the normal values.

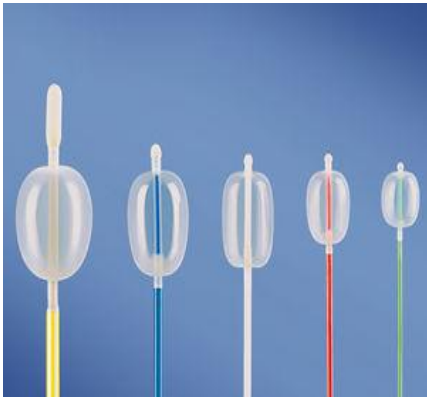**c) Control of the cardiological condition as AF.**

**d) Urgent Embolectomy: using Fogarty balloon catheter** is the most important line of treatment.

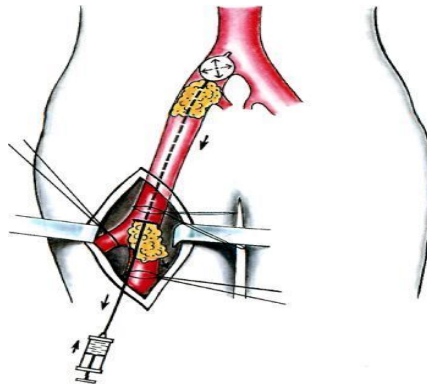
i)- can be done under local or regional anesthesia.

ii)- Must be done as early as possible to save the limb.

iii)-The catheter is introduced inside the artery under image, passed distal to the site of embolus, the balloon is inflated and finally the catheter is withdrawn out removing the embolus.



Fogarty catheters



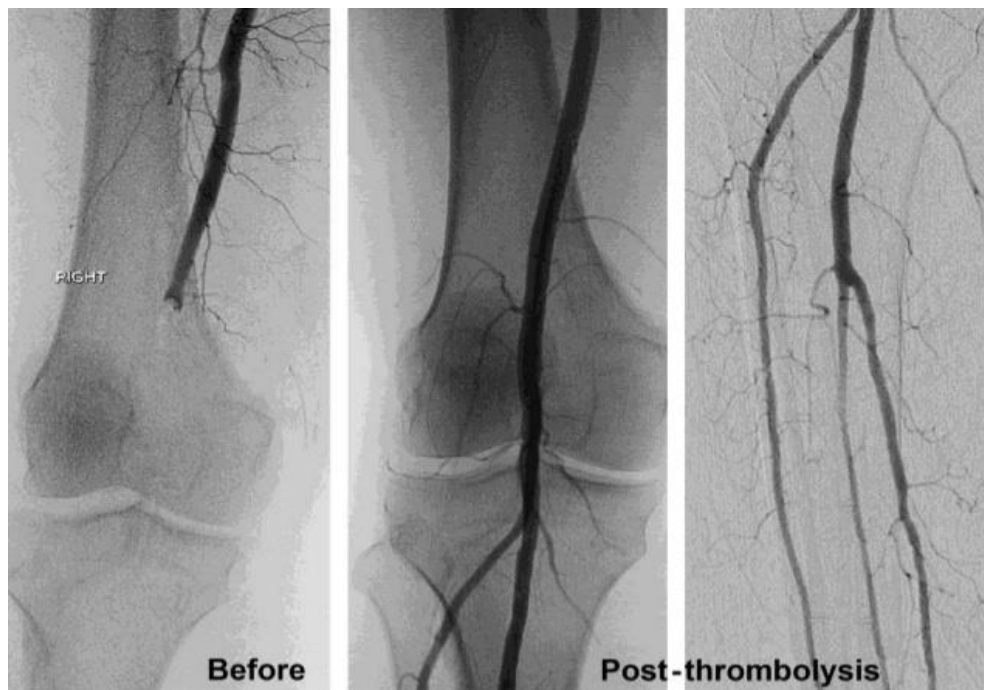
embolectomy

## **II- Acute thrombotic ischemia:**

**Arteriography** is done followed by:

**i) Thrombolysis** using thrombolytic agent as streptokinase or urokinase injected locally at the site of thrombus.

**ii) Revascularization surgery** according to the findings of arteriography to treat the state of chronic ischemia



## **Arterial injuries**

### **Causes:**

- 1- Penetrating trauma : caused by knives , gun shots & stab wounds.
- 2- Blunt trauma as in motor car accident or fall from height or associated with bone fractures as in (supra-condylar fracture humerus).
- 3- Iatrogenic: during surgical procedures.

### **Pathological types:**

**A- Tears:** commonly with penetrating trauma.

- 1- Complete:**
- The cut ends retract constricts and thrombose.
  - The patient usually presents with picture of acute ischemia or bleeding.

**2- Partial:**

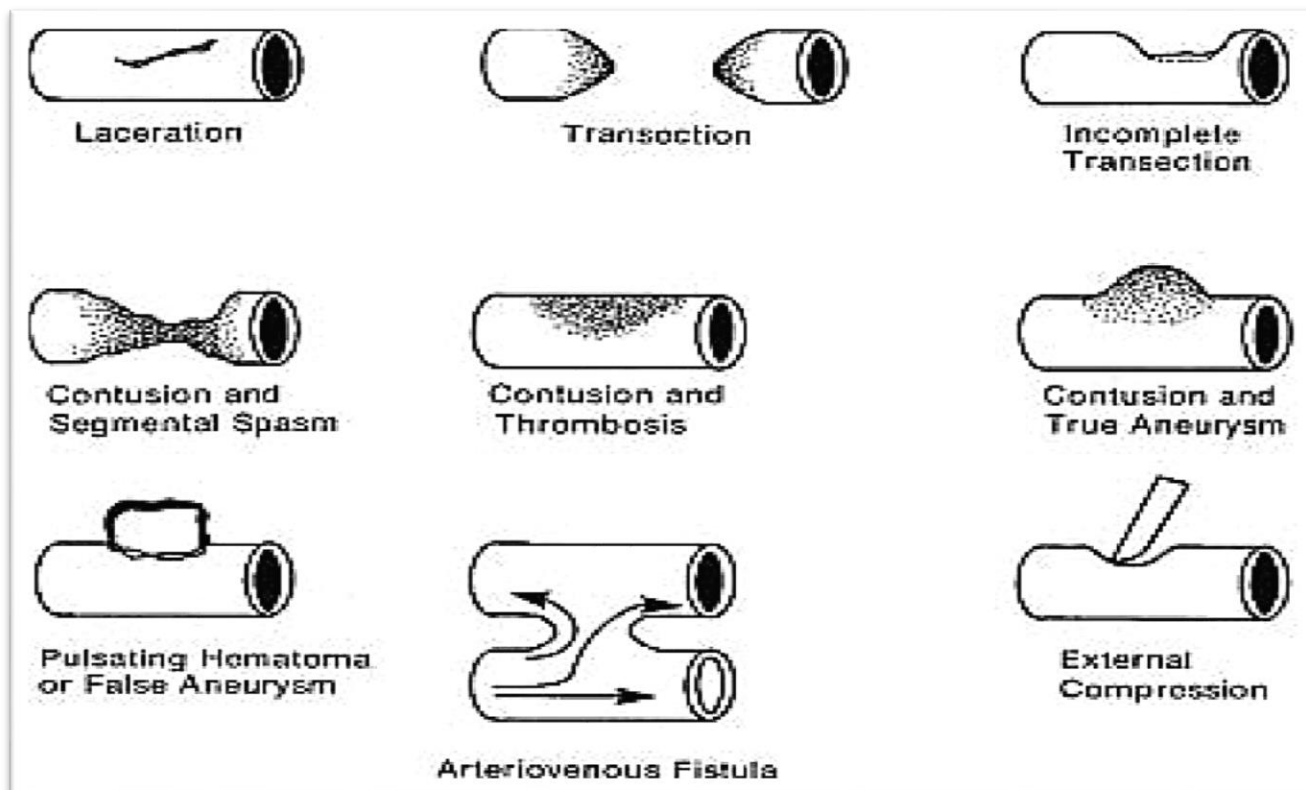
- Retraction at the site of tear produces widening of the gap causing marked bleeding.
- A pulsating hematoma (= **pseudo-aneurysm**) may occur
- A-V fistula may occur.

### **B- Arterial contusion and thrombosis:**

- commonly occurs in closed injuries and the patient presents with picture of acute ischemia.

### **C- Arterial spasm:**

- No actual injury. The patient presents with acute ischemia.



**Types of injuries**

**Clinical picture of arterial injuries:**

**A. Hard signs:** include the following:

- Bleeding from the artery, absence of pulse, pulsations
- Haematoma, bruit or thrill and
- Ischemia-related signs that are increasing in size.

**B. Soft signs** include the following:

- bleeding at the scene,
- reduced pulse,
- non-expanding hematoma,
- injury close to a blood vessel or bone fracture.

In the presence of hard signs, intervention (surgical or endovascular) is generally recommended, whereas soft signs indicate the need for further investigation. One must be aware that negative clinical examination does not rule out vascular trauma

**General symptoms & signs:**

- History of trauma
- Hypovolemic shock may be present.

### **Local symptoms & signs:**

- 1- Pain at site of trauma
- 2- Bleeding → External through skin wound  
or Internal → forming hematoma
- 3- Picture of acute ischemia distal to site of injury (6 Ps).
- 4- Swelling → hematoma. – Pseudo-aneurysm
- 5- A-V fistula

### **Investigations:**

I- No need for investigations in Urgent cases with shock or evident bleeding or acute ischemia needs urgent exploration to save the limb.

**II- Duplex can** be done to diagnose the site and type of injury.

- Duplex sonography (DUS) is widely used in the setting of trauma. Accessibility, low cost, easy mobility, non-invasiveness and lack of ionising radiation are its advantages.
- Luminal narrowing, hypoechoic intramural haematoma, dissected arterial wall, haemodynamic relevant stenosis, the presence of pseudoaneurysm, and occlusion are the features consistent with vascular injury.
- With the addition of colour-Doppler, the sensitivity, specificity and accuracy are up to 95%, 99% and 98%, respectively, in assessment of peripheral vascular injuries.

### **III- Computed Tomography Angiography (CTA)**

- Newer multi-detector CT scanners have largely replaced digital subtraction angiogram, which had been previously regarded as the gold-standard imaging modality for vascular injury.
- CTA has a high sensitivity and specificity
- The CTA has the added advantage of being non-invasive and allows for assessment of other related injuries in a polytrauma patient

### **IV- Digital Subtraction Angiography**

- It is an invasive procedure with the following complications: puncture site bleeding and haematoma, unintended vessel puncture leading to arteriovenous fistula and complications related to embolism.

**Treatment:**

**I- First Aid:**

- Local control of external bleeding by **direct local compression** at the site of injury (Don't use tourniquet as it produces more arterial damage and ischemia).

**II- definite treatment**

- a) if there is associated fractures it should be repaired first, followed by vascular repair.
- b) **The arterial repair** may be:
  - 1- Suturing the tear if small
  - 2- End to end anastomosis in complete division
  - 3- Arterial graft: in lost or damaged segment (saphenous v. graft or synthetic graft).
- c) - Small veins are ligated
- d) - Large veins are repaired.

.....

**Chronic ischemia**

**Definition:** slow gradual progressive arterial obstruction that gives enough time for collaterals to develop so gangrene does not occur early.

**Causes:**

- I- Atherosclerosis:** more in lower limbs, in old age, *the most common*
- II- Diabetes: common in** lower limbs, young or old age
- III- Buerger's disease:** more in lower limbs, middle age
- IV- Raynaud's disease:** upper limb, young females.

**Chronic ischemia due to atherosclerosis**

**Predisposing factors:** diabetes – obesity- smoking

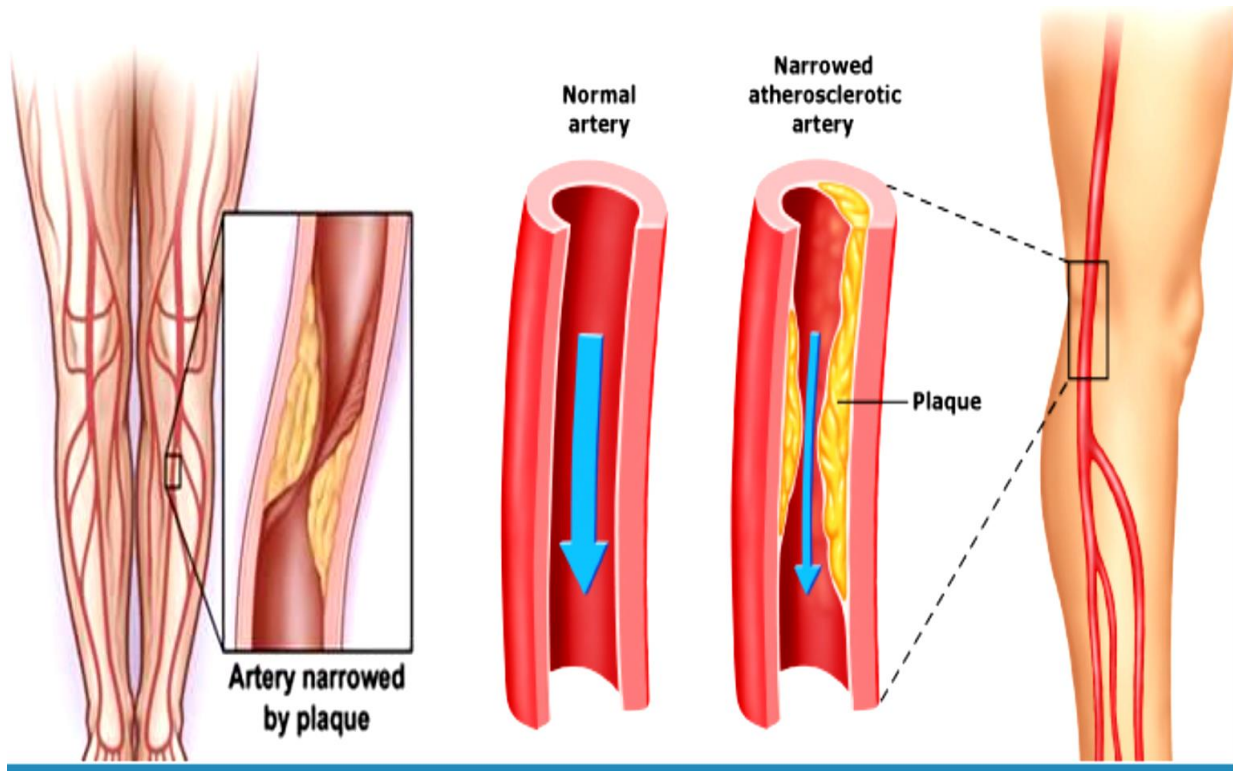
**Pathology:** - The primary lesion is atheroma adjacent to arterial bifurcations or branches.

**The commonest sites affected are:**

- i) Coronary → angina
- ii) Cerebrals → stroke

iii) Carotids → Stroke

iv) Arteries of lower limb → lower limb ischemia → Common sites are aortic bifurcation, superficial femoral, popliteal and tibial arteries.



### **Clinical picture of chronic ischemia of lower limbs:** **Symptoms**

I- **Pain** : due to muscle ischemia

#### **□ Types of pain:**

##### **1- Intermittent claudications:**

- Cramp like pain
- Induced by exercise & relieved by rest.
- The more the walking distance, the less the ischemia & vice versa.
- The more the time rest, the more severe the ischemia
- **Site:** according to the level of arterial obstruction:
  - i) Aortoiliac → pain in whole lower limb muscles.
  - ii) Superficial femoral → pain in calf muscles

iii) Tibial & popliteal → pain in foot.

**2- Rest pain:** limb pain at rest

- ❖ it indicates severe form of chronic ischemia that affects the limb at rest.
- ❖ It indicates ischemic neuritis (crying nerves).
- ❖ It is more severe at night due to limb elevation, decreases blood flow. Also warmth of the limb → cutaneous V.D. → shift of the blood to subcutaneous tissue → more ischemia and more pain.
- ❖ some comfort may occur by keeping the foot dependant below the level of bed

**II-Ulcers** : over tip of toes and dorsum of foot.

**III- dry gangrene:** Slowly developed.

**N.B. Grades of intermittent claudications:**

**Grade I:** *After walking for sometimes patient has pain and pain disappears when the patient continues to walk. The pain producing substances are washed off by the adequate collateral.*

**Grade II:** *Patient has pain after walking but he can continue to walk in spite of slight pain.*

**Grade III:**

*Patient has pain after walking for sometimes with continued walking, the pain aggravates and patient has to take rest to get relief from pain.*

**Local signs of chronic ischemia:**

**1- Trophic changes:**

a) **Skin & subcut. fat** → Loss of hair, dryness of the skin, brittle and deformed nails and loss of subcutaneous fat.

**Ischemic ulcers** at the tip of toes or dorsum of foot.

b) → **Muscles** → wasting and weakness.

**2- Coldness** of the limb below the level of obstruction.

**3- Colour changes** → **pallor** due to decreased blood flow to the skin.

**Cyanosis or redness** may occur due to stagnation of blood in the dilated capillaries.

**4- Absence of pulsation distally** → dorsalis pedis, posterior tibial, popliteal, and femoral arteries.

**N.B.** we detect level of arterial obstruction from site of trophic changes, coldness and pulsations.

**5- Special tests:**

**1- Capillary circulation:**

- ❖ Normally, pressing over the tip of the toe, it become pale and once releasing the pressure the color returns immediately.
- ❖ In ischemia → there is delay in the return of color (sluggish capillary circulation).

**2- Buerger's angle:**

- ❖ the patient lies supine → gradually elevating the limb → the angle at which blanching occurs is called Buerger's angle.
- ❖ The less the angle the more severe ischemia.

**3- Venous refilling time** → In chronic ischemia delay in refilling time

**N.B. Critical limb ischemia:** it means impending limb gangrene

- A) Severe form of ischemia.
- B) Rest pain for > 2 weeks.

**Investigations for chronic ischemia**

**I- Lab.** → CBC – blood sugar—serum cholesterol .

**II- Radiological:**

**A- Doppler** → gives an idea about the presence of blood flow in an artery.

**B- Doppler U/S** → measures the ankle / brachial index:

- Normally → = 1
- Less than 0.9 → ischemia
- Less than 0.7 → severe ischemia
- Less than 0.3 → impending gangrene.

**C- Duplex scan**

- visualizes the arteries and veins and detects sites of obstruction, stenosis and thrombosis.

- Best diagnostic

**D- Arteriography (angiography):**

Used preoperatively to plane type and extent of surgery (it is invasive technique with arterial puncture to inject the dye).

**E- Digital subtraction angiography →**

Computerized imaging, non-invasive technique (the dye injected I.V.)

**Values of arteriography:**

- 1- detect the site of obstruction
- 2- determine the state of proximal arteries
- 3- State of distal run off (collaterals)

**Treatment of Chronic ischemia**

**I- Conservative**

**II- Endovascular surgery**

**III- Open surgery**

**I- Conservative**

**Indications:** 1- Mild cases of chronic ischemia

2- Patient unfit for surgery

**Methods:**

- 1- Control D.M. and hypertension, stop smoking.
- 2- Aspirin → prevents platelet adhesiveness →decreases obstruction.
- 3- Persantin → prevents platelet aggregations.
- 4- Trental → improve capillary circulation and blood flow.
- 5- care of feet and avoid trauma and injuries.

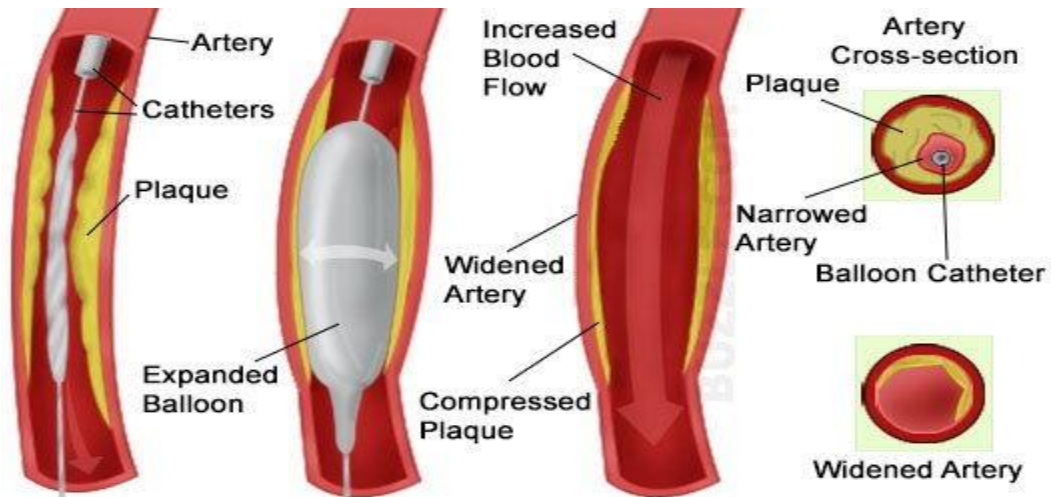
**II- Endovascular surgery**

**Indications:**

- 1- Severe symptoms of ischemia
- 2- Impending gangrene

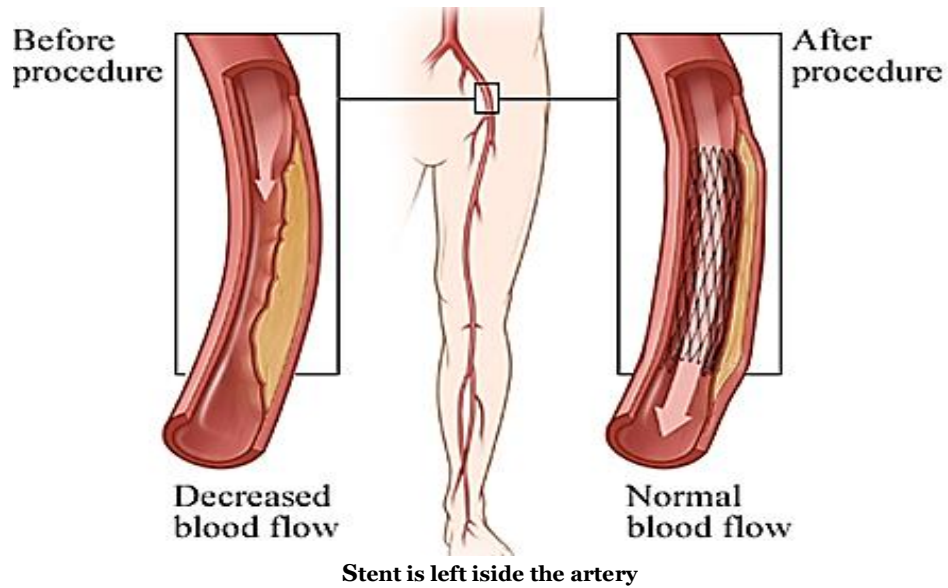
**Procedures:**

**A- Per-cutaneous trans-luminal angioplasty →** using a special ballon catheter to dilate a stenosed segment.



Balloon angioplasty

**B- Intravascular stents** → a stent is placed in a stenosed segment to prevent re-stenosis and maintain patency.



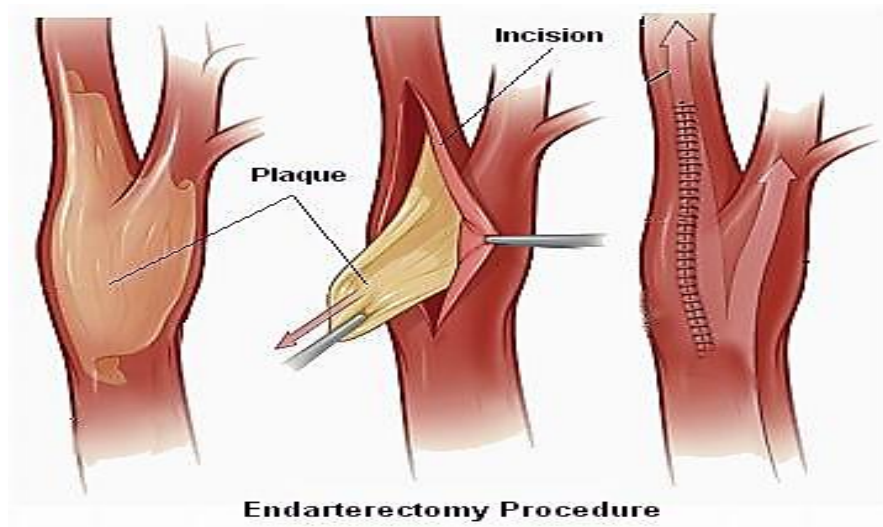
### III- Open surgery

**Indications:** the same as above

**Procedures:**

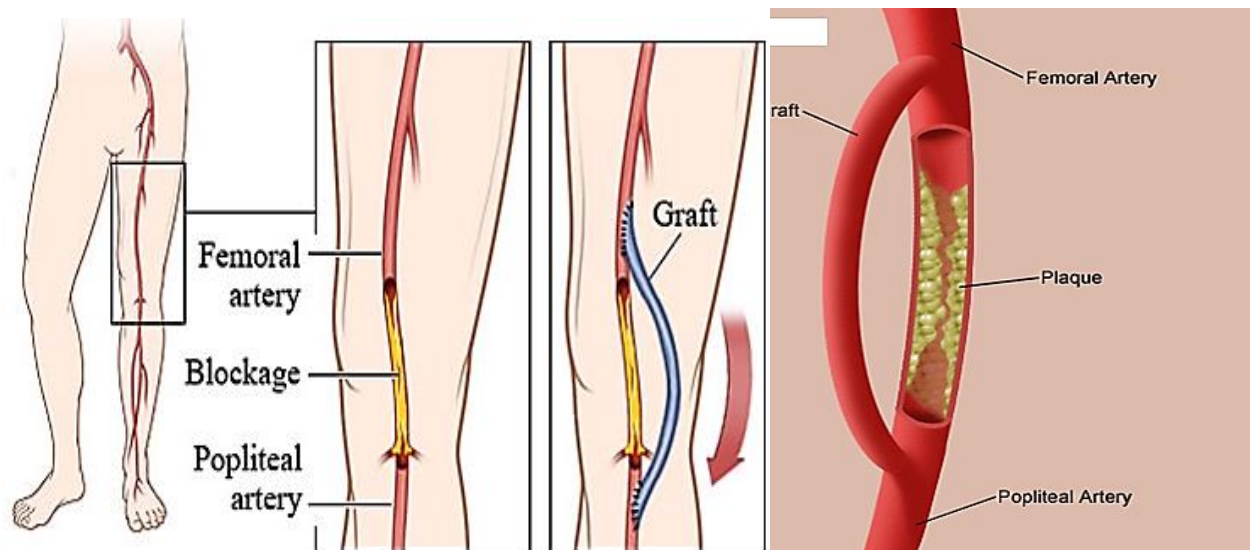
#### A- Thrombo-end-arterectomy

- it means removal of an obstructing thrombus to leave a patent artery.
- Used in large arteries and localized obstruction.



#### B- By-Pass grafts:

- It is more frequently used
- The idea is to use a graft to bypass an obstructed segment of the artery.
- The graft transmits blood from the proximal healthy arterial segment to healthy distal segment
  - Example: Femoro-popliteal bypass in obstructed superficial femoral artery.
  - Types of grafts:
    - 1- Saphenous vein graft → the best graft. (In situ or reversed)
    - 2- Synthetic graft (Dacron or PTFE) → used in big arteries



Femoro-popliteal bypass

***N.B. Both endovascular and open surgery need a good distal run off as a must.***

---

### **Chronic ischemia due to Buerger's disease** **{Thrombo-angitis obliterance}**

**Aetiology:** unknown (heavy cigarette smoking)

**Pathology:**

- Sex → mostly males
- Age → middle age (20 - 40 Y).

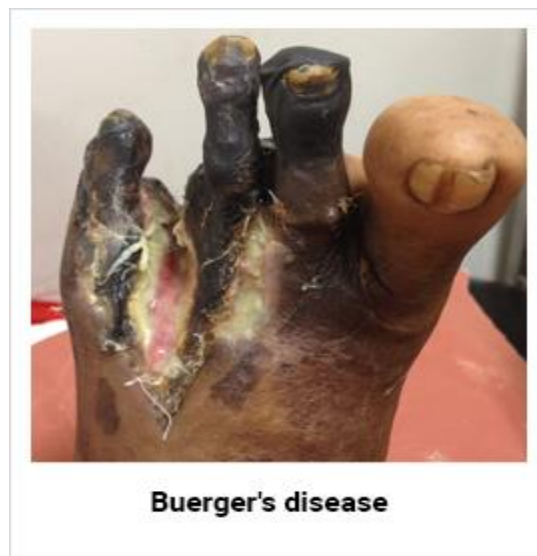
**The vessels affected:** panvasculitis

- The vessels show segmental affection by multiple thrombi and micro-abscesses
- Dense infiltrations of all layers with inflammatory cells and multi-nucleated cells
- The inflammatory thrombi show segmental affection of the wall of the vessel
- The thrombi progressively occlude the lumen
- Fibrosis of the vessels occur in chronic cases

- ❑ Neuritis of the nearby nerves which explains the severe pain in Buerger's disease
- ❑ Vessels of the lower limbs distal to the popliteal artery (i.e. tibial vessels).
- ❑ There is associated migrating thrombophlebitis.

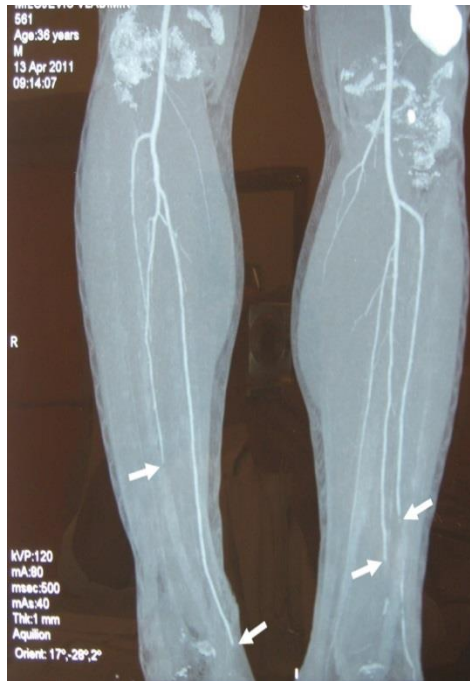**Clinical picture:**

- 1- Signs and symptoms of chronic ischemia in **both legs** in heavy smokers & middle age patients.
- 2- Picture of migrating thrombophlebitis (painful, red & tender cord like veins).
- 3- Characterized by resting pain, ischemic ulcerations, and gangrene of the digits of hands and feet



**Investigations:** the same as before.

- 1- Duplex Scan
- 2- Angiography – C.T. angiography → **distal** stenosis and obstruction of leg vessels



CT angiogram showing segmental stenosis of arteries of the lower leg (indicated by arrows)

### **Treatment:**

- 1- Stop smoking
- 2- Drugs: anti-platelets drugs – vasodilators

### 3- **Lumbar Sympathectomy :**

Removal: 1st, 2nd, 3rd and 4th lumbar ganglia produce sympathetic denervation of the lower limb.

- In bilateral Lumbar sympathectomy one side L1 ganglion is to be preserved
- The main surgical line of treatment if needed.
- It means division of the lumbar sympathetic nerves that supply the lower limb.
- Lumbar sympathectomy results in cutaneous vasodilatation and may improve cutaneous circulation.
- Rest pain may be relieved.
- If an amputation is required, the level of amputation may be lowered following sympathectomy
- In bilateral Lumbar sympathectomy one side L1 ganglion is to be preserved to avoid the occurrence of impotence

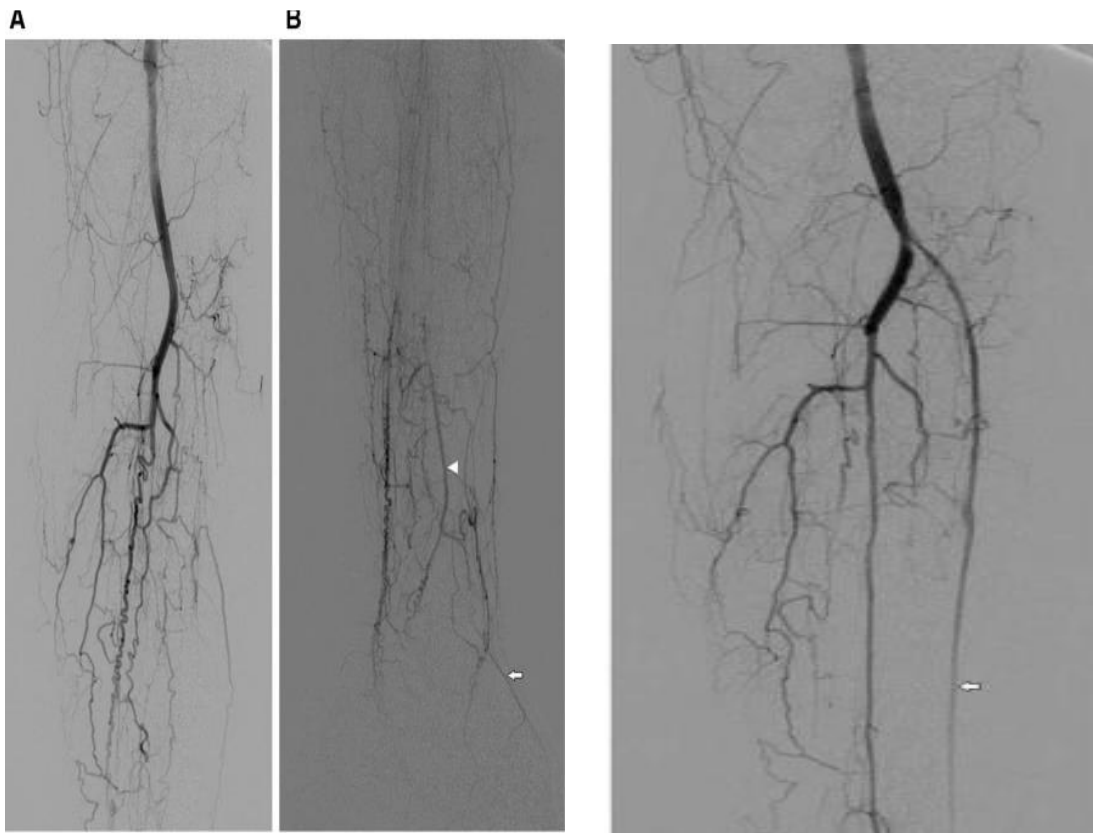
4- Limited amputation in case of gangrene of on or more toes.

5- **The role of direct vascular surgery in Buerger's disease:**

As the disease involves mainly the small and medium sized vessels direct arterial surgery is not helpful in Buerger's disease.

6- Promising treatment:

- **Endovascular surgery is** tried in selected cases
- **Stem cell therapy:** helps new vessels formation → improves vascularity



**Trial with stem therapy**



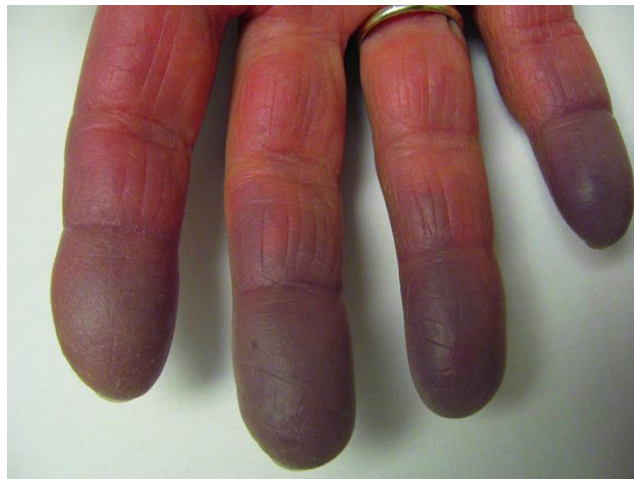## Raynaud's disease

**It is one of the vaso-spastic arterial diseases.**

**Aetiology :** - Unknown  
- Hypersensitivity of the arterioles to cold  
- Increased sympathetic tone

### **Criteria for diagnosis:**

- 1- Much common in females
- 2- Bilateral and symmetrical affecting **both hands**.
- 3- The condition precipitated by cold
- 4- **The attack involves:**
  - a) Pallor → arteriolar spasm.
  - b) Cyanosis → dilated capillaries filled with deoxygenated blood.
  - c) Redness → arteriolar V.D. and capillaries filled with oxygenated blood.
- 5- Intact radial pulses.
- 6- Gangrenous patches may occur in severe cases.



Raynaud's disease

### **Treatment:**

- 1- Conservative → avoid cold weather + V.D. drugs.
  - 2- In severe cases → **Cervico-dorsal sympathectomy** → removes the sympathetic tone → gives good results.
-

## Gangrene

**Definition:** *it means death and putrefaction of tissues due to loss of blood supply with or without bacterial invasion.*

**Aetiology:**

- 1- Ischemia:** • Acute ischemia → Moist gangrene
  - Chronic ischemia → dry gangrene.  
(Embolic – thrombotic -- Raynaud's)
- 2- Infective:** Clostridial gas gangrene.
- 3- Neuropathic,** infective & ischemic → **diabetic foot.**
- 4- Traumatic** → bed sores – crushing trauma of the vessels.

**Clinical types:**

**I- Dry Gangrene:**

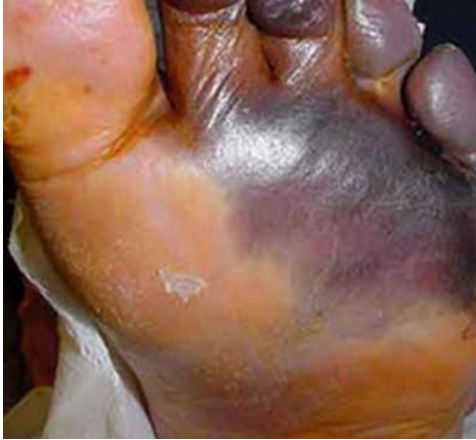- Occurs in chronic ischemia.
- The tissues are dry, mummified, hard, shrunken and black

**II- Aseptic moist Gangrene:**

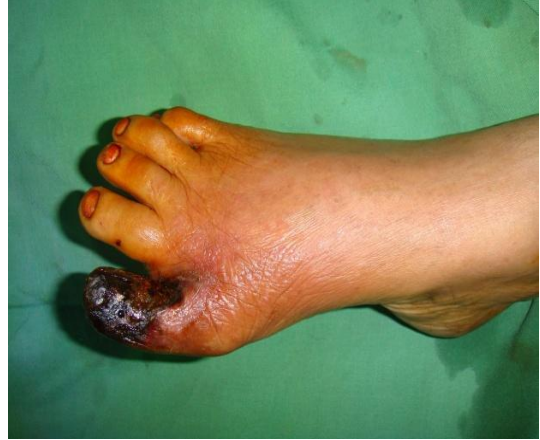- Occurs in acute embolic ischemia. The tissues are filled with fluids, swollen, whitish and later cyanosed then blackish.
- No signs of infections.

**III- Septic moist Gangrene:**

- Infection of preexisting aseptic moist gangrene.**
- Infection and ischemic gangrene occurs with each other or presence of virulent organism produces death of tissues from the start.
- The skin appears moist, bullae filled with serum, swollen and edematous tissues, and very offensive odour and blackish. the patient may get septicemia.
- Diabetic foot is an example of this type.



**Moist gangrene**



**dry gangrene**

### **Cardinal signs of gangrene:**

- 1- **P**ulseless
- 2- Loss of **S**ensation of the affected part
- 3- Loss of **H**eat.
- 4- **C**olor of skin changes → fixed blackish.
- 5- Loss of **F**unction of the limb affected.  
(Press and see how color fades).

### **Diabetic Foot Infection**

It is infection of the foot in diabetic patient.

- Affects 15-25% of diabetic patients during their lifetime.
- Major cause of lower limb amputations worldwide.
- Leads to high morbidity, prolonged hospital stays, and increased healthcare costs.

### **Predisposing factors:**

- 1- Peripheral neuropathy → decreases the sensations in the feet → predisposes to infection.
- 2- Vascular affection → chronic ischemia → decreases vitality of tissues
- 3- Decreased immunity → predisposes to infection.
- 4- Repeated trauma + bacterial entry → Ulceration & deep infections

### **Causative organisms:**

- Diabetic foot infections are often polymicrobial. Escherichia coli, Proteus, Pseudomonas, Staphylococcus aureus are the most frequent pathogens contributing to progressive and widespread tissue destruction. Staphylococcus aureus, remains the main causative agent of diabetic foot osteomyelitis (DFO)

### **A. Mild Infections (Superficial Wounds)**

- Staphylococcus aureus (including Methicillin-resistant Staphylococcus aureus - MRSA)
- Streptococcus species (e.g., Streptococcus pyogenes)

### **B. Moderate to Severe Infections (Deep Tissue Involvement)**

- Gram-positive bacteria: Staphylococcus aureus/ Streptococcus species
- Gram-negative bacteria: Escherichia coli/ Klebsiella species/ Proteus species/ Pseudomonas aeruginosa (especially in chronic wounds or patients with previous antibiotic use)
- Anaerobic bacteria (common in foul-smelling infections or necrotic tissue): Bacteroides species/ Clostridium species
- Polymicrobial infections: Most moderate and severe diabetic foot infections are caused by a combination of these organisms.

### **Clinical picture:**

- History of diabetes + history of trauma to the foot.
- Chronic ulcer in plantar aspect of foot.
- Osteomyelitis of the underlying bones.
- Rapid spread of infection in the foot.
- Septic moist gangrene is the end result.

### **Wagner Grades and Clinical Features**

#### **Grade 0:**

- No open lesion
- Intact skin, may have deformities, calluses, or cellulitis
- Preventative care (e.g., offloading, foot hygiene).

#### **Grade 1:**

- Superficial ulcer
- Partial/full-thickness ulcer,
- No deeper tissue involvement
- Debridement, wound dressings, offloading (e.g., contact casting) .

### **Grade 2:**

- Deep ulcer
- Extends to tendons, ligaments, or joint capsule (no bone involvement)
- Surgical debridement, antibiotics if infected, offloading.

### **Grade 3:**

- Deep ulcer + abscess/osteomyelitis
- Bone involvement (osteomyelitis) or deep abscess
- IV antibiotics, surgical debridement, possible partial amputation . |

### **Grade 4:**

- Partial gangrene
- Necrosis of forefoot (toes, metatarsals)
- Urgent vascular evaluation, possible forefoot amputation.

### **Grade 5:**

- Whole-foot gangrene
- Extensive necrosis involving the entire foot
- Major amputation (below-knee or above-knee).

### **Investigations:**

#### **A. Bedside Tests**

- Ankle-brachial index (ABI): Measures blood flow in the legs (<0.9 suggests poor circulation)

#### **B. Laboratory Tests**

1. Complete blood count (CBC): Elevated white blood cell count indicates infection
2. C-reactive protein (CRP) and erythrocyte sedimentation rate (ESR): Markers of inflammation and infection severity
3. Blood glucose and Hemoglobin A1c (HbA1c): Assess diabetes control
4. Wound culture: Helps guide antibiotic therapy

#### **C. Imaging**

1. X-ray: Detects bone infection (osteomyelitis) and gas in soft tissue (gas gangrene)
2. Magnetic resonance imaging (MRI): Gold standard for detecting osteomyelitis
3. Duplex ultrasound: Assesses blood flow in the lower limbs

### **Treatment:**

#### **I- Prevention of foot infection**

Care of feet – careful cutting of nails – avoid walking bare footed – early treatment of infection.

## **II- Active treatment:**

- I. Hospitalization
- II. Control of blood sugar
- III. Broad spectrum antibiotics: better according to C/S:

<b>Severity</b>	<b>Recommended Empirical Antibiotics</b>
<b>Mild</b>	Amoxicillin-clavulanate, Cephalexin, Clindamycin
<b>Moderate</b>	Intravenous Ceftriaxone ± Metronidazole, Fluoroquinolones
<b>Severe</b>	Broad-spectrum: Piperacillin-Tazobactam, Carbapenems, Vancomycin for Methicillin-resistant Staphylococcus aureus (MRSA)

### **• Duration of antibiotics:**

- Mild infections: 1-2 weeks
- Moderate infections: 2-4 weeks
- Bone infection (osteomyelitis): 6 weeks or longer

## **IV. Foot drainage and debridement:**

- a) Drain all pockets of pus
- b) Amputation of the gangrenous parts
- c) Debridement means excision of the dead and necrotic tissues.
- d) Repeated dressings with antiseptics.

## **Indications for Amputation in Diabetic Foot Infections**

- Amputation in diabetic foot infections is considered when conservative and surgical interventions fail to control infection, ischemia, or tissue necrosis, posing risks of systemic sepsis or limb loss.
- The decision depends on clinical severity, vascular status, and patient factors.

### **key indications:**

#### 1. Severe Infection with Systemic Compromise:

- Wet gangrene (infection + ischemia) or necrotizing fasciitis, which can rapidly progress to sepsis
- Life-threatening sepsis requiring urgent source control

2. Extensive Tissue Necrosis or Non-Salvageable Limb:

- Whole-foot gangrene (Wagner Grade 5) or fore-foot gangrene (Grade 4) with irreversible damage.
- Deep abscess or osteomyelitis unresponsive to debridement and antibiotics.

3. Critical Limb Ischemia (CLI) with Failed Revascularization:

- Non-reconstructable vascular disease (e.g., extensive arterial occlusion) where blood flow cannot be restored.

4. Failed Conservative and Minor Surgical Measures:

- Persistent osteomyelitis after > 6 weeks of antibiotics or localized resection
- Recurrent ulcers/infections in a functionally useless limb (e.g., Charcot deformity with recurrent breakdown).

5. Patient Factors:

- Bedridden status or poor mobility, where limb salvage offers no functional benefit.

**Key Considerations**

- Wagner Classification: Grade  $\geq 4$  often necessitates amputation.
- Vascular Assessment: Transcutaneous oxygen measurements (<30 mmHg) or non-healing ulcers despite revascularization.
- Alternatives to Primary Amputation:
  - ❖ Minor amputations (toe, ray, trans-metatarsal) for localized necrosis
  - ❖ Aggressive debridement + IV antibiotics for salvageable limbs

.....

## Aneurysms

**Definition:** It means localized dilatation of an artery.

### **Classification:**

#### **I- According to the aetiology:**

**A- Congenital** → as in cerebral artery aneurysm.

#### **B- Traumatic**

- leads to weakness of the wall of the artery leading to its dilatation.
- Trauma may lead to formation of false aneurysm (saccular pulsating hematoma).

**C- Pathological** → due to weakness of the wall by atherosclerosis (e.g. aortic aneurysm).

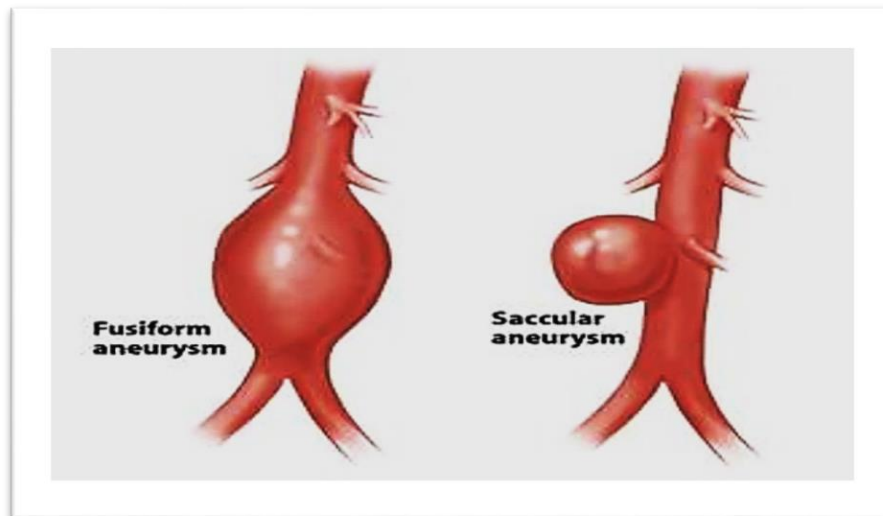
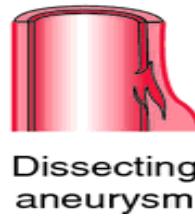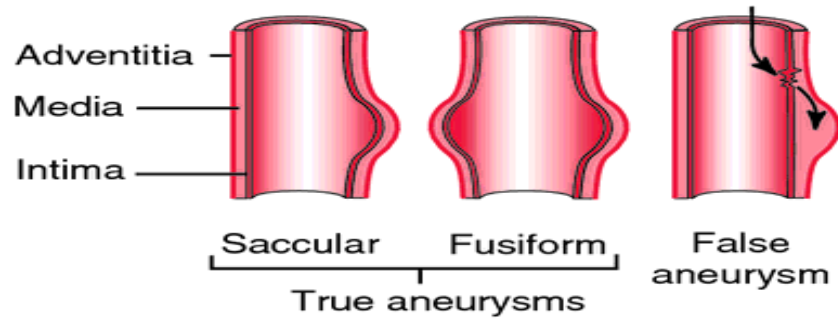
#### **II- According to the structure:**

**A- True:** The wall of the aneurysm is formed of the same 3 layers of the artery

**B- False:** It is a hematoma communicating with the lumen of the injured artery.  
The wall is formed of fibrous tissue

#### **III- According to the shape:**

A- Fusiform      B- Saccular      C- Dissecting.



### **Complications of aneurysm:**

- 1- Rupture → leads to hemorrhage and may be fatal.
- 2- Distal ischemia due to thrombosis and occlusion of the aneurysm or detached thrombus from the aneurysm and moves distally obstructing smaller artery.
- 3- Compression on the surrounding structure as vein or nerve causing motor or sensory defects.

### **Symptoms:**

- 1- Asymptomatic
- 2- Swelling
- 3- Motor or sensory manifestation.(nerve compression)

4- Hemorrhage.

**Signs: Characters of true aneurysm:**

- 1- Swelling along the line of an artery moves across not along it.
- 2- The swelling gives expansile pulsations. **(Most important sign)**
- 3- Proximal compression over the artery → diminishes the size of the aneurysm.
- 4- Distal pressure over the artery → increases the size of the aneurysm.
- 5- Palpable thrill and heard bruit over the aneurysm.

- D.D.**
- A- Swelling overlying an artery → gives transmitted pulsations.
  - B- Vascular tumour as in osteosarcoma.
  - C- A-V shunt

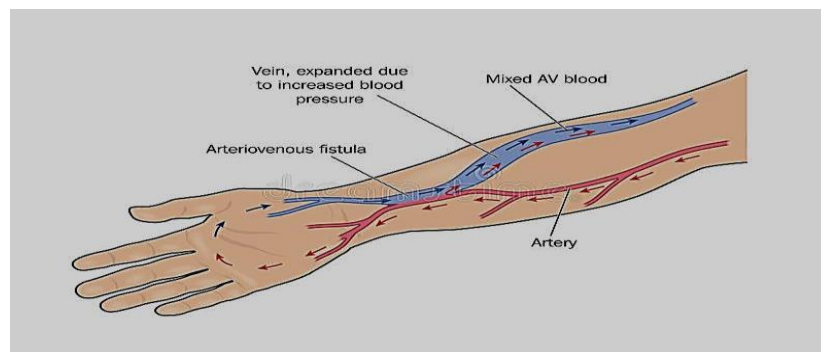
**C- A-V shunt (fistula):**

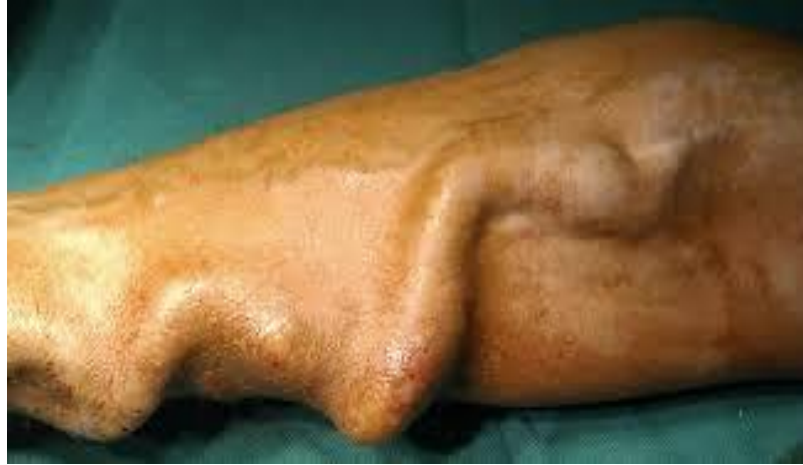It is abnormal communication between artery and vein transmits arterial blood to venous side → pulsating swelling.

- **Types:** congenital – acquired

**Acquired A-V fistula**

- 1- Traumatic: following penetrating sharp trauma.
- 2- Therapeutic: for use in dialysis in case of chronic renal failure





- **Clinically:**

- 1- the pulse: tachycardia
- 2- Look for collapsing character of the pulse. W.H
- 3- Blood pressure—there may be wide pulse pressure.
- 4- Dilated engorged, pulsating veins
- 5- Swelling of the limb or organ involved in chronic cases
- 6- Palpable thrill
- 7- By auscultation over the fistula ; machinery murmurs are heard
- 8- Decreased cardiac output and hypotension in big A-V-fistula
- 9- **Branham's sign:** *Pressure on the artery proximal to the fistula causes :*
  - *The venous swelling diminish*
  - *Thrill and bruit disappears*
  - *Pulse rate falls*
  - *Pulse pressure returns to normal.*

**Complications :** heart failure - deep vein thrombosis – bleeding

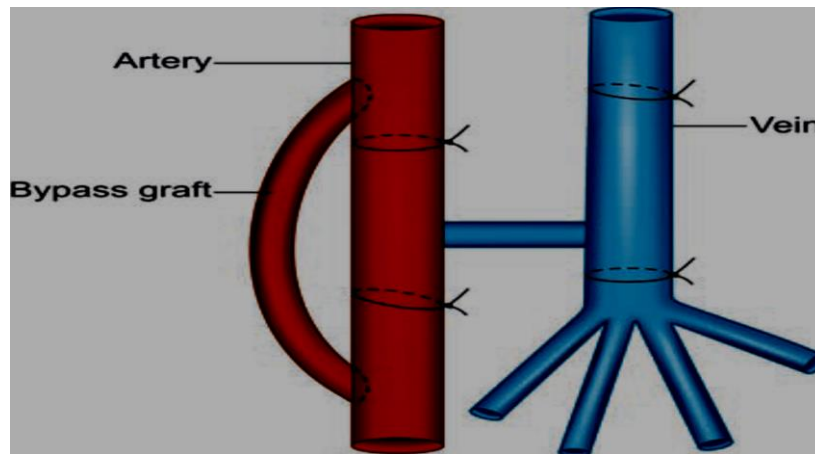
**Investigations:**

- 1- Duplex scan
- 2- C.T. angiography
- 3- Magnetic resonance angiography (MRA); In deep fistulae

**Treatment:**

- A. **Ultrasound-guided compression.** An ultrasound probe is used to compress the fistula and block blood flow to the damaged blood vessels. This procedure only takes about 10 minutes. But it only works for about 1 in 3 people.
- B. **Catheter embolization.** In this procedure, a catheter is inserted in an artery near the site of your arteriovenous fistula and a small coil or stent is placed at the site of fistula to reroute blood flow.

- C. **Surgery.** Large arteriovenous fistulas that can't be treated with catheter embolization may require surgery (Quadruple ligation with a bypass graft for the artery)



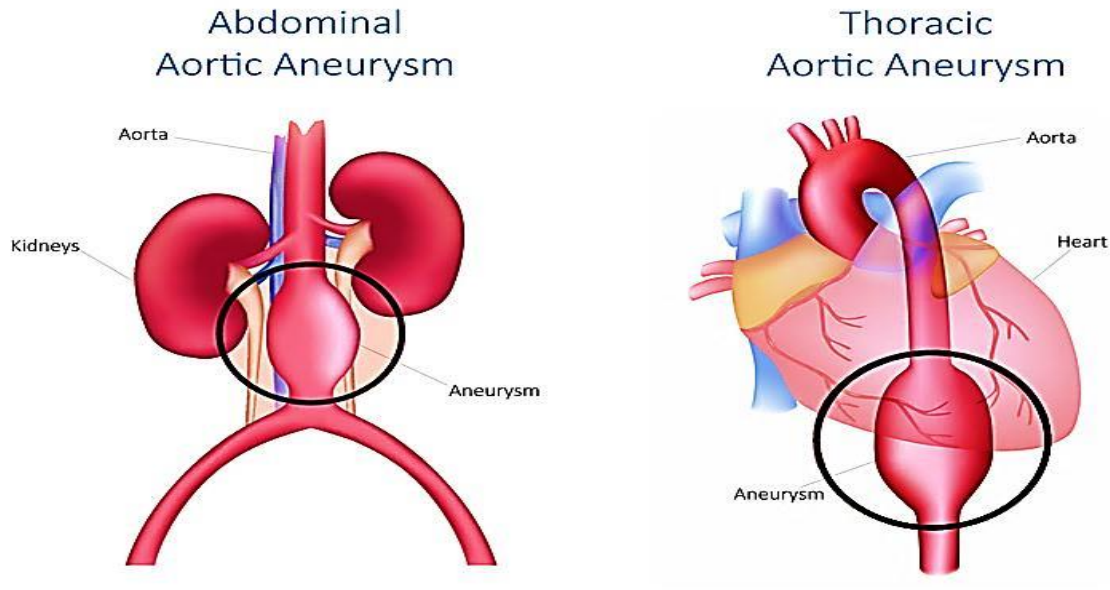
---

**Aortic aneurysm (AA):**

Aortic aneurysm is an irreversible dilatation of the aorta involving all three wall layers; it may focal or diffuse. The main risk is death from rupture; the risk of rupture within 5 years of detection is approximately 15% for thoracic aneurysms that are less than 6 cm in diameter and 30% for aneurysms equal to or larger than 6 cm.

**Etiology:**

1. Atherosclerosis
2. Smoking is the most important behavior related to aortic aneurysm.
3. High blood pressure
4. High blood cholesterol



**Types of aortic neurysms**

### **Clinical presentations:**

#### **Abdominal Aortic Aneurysm: AAA**

- Abdominal aortic aneurysms are more common in men and among people age 65 and older.
- Abdominal aortic aneurysms are more common among white people than among black people
- Abdominal pain radiating to the back.
- Large, pulsatile swelling above the umbilicus.
- A bruit may be heard from the turbulent blood flow in the aneurysm.
- Rupture may be the first event of AAA.
- Once an aneurysm has ruptured, it presents with classic symptoms of abdominal pain which is severe, constant, and radiating to the back with signs of shock.

#### **Thoracic Aortic Aneurysm**

- Chest pain. Chest pain caused by an aortic aneurysm is usually associated with an ascending aneurysm, or an aneurysm affecting the arch. This type of chest pain, in distinction to typical angina, is usually not directly related to exertion.

- Back pain. Back pain caused by a thoracic aortic aneurysm is often felt between the shoulder blades, or a bit lower. It usually occurs with an aneurysm of the descending thoracic aorta.
- Hoarseness. Dilation of the ascending aorta or the aortic arch can affect the recurrent laryngeal nerve. There resulting vocal cord paralysis can lead to hoarseness.
- Cough & dyspnea. An aneurysm of the ascending aorta or the arch can compress on the airways, producing cough.

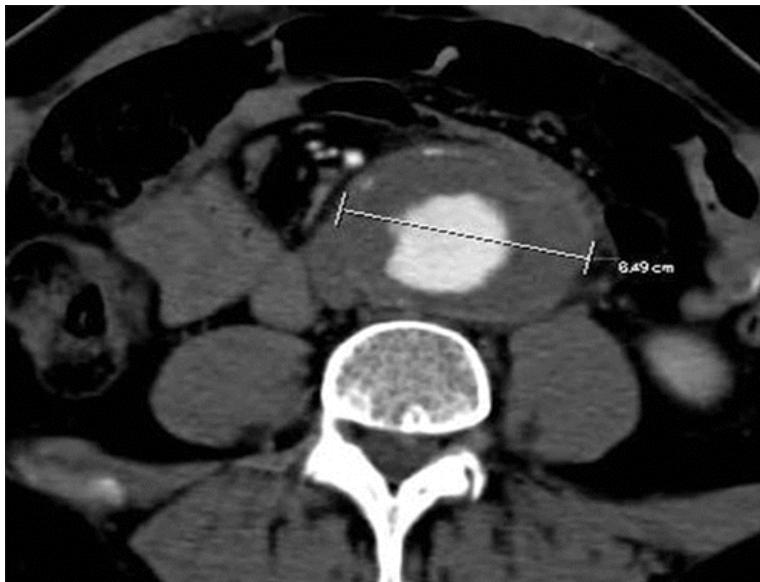### **Aortic Dissection**

An aortic dissection is a tear in the intima of the aorta, which can occur in any area of weakness in the aortic wall. Flowing blood can enter the tear, forcibly separating the layers of the aortic wall.

When such a dissection occurs, most often the victim will experience a sudden, severe, tearing pain in the chest or back with loss of consciousness and shock state

### **Investigations:**

- 2- CT Angiography is accurate and diagnostic
- 3- MRI
4. US for aortic aneurysm.



**Aortic aneurysm**

### **Treatment:**

### In small AAA:

- Drugs to lower your blood pressure and cholesterol level, which may help stop the aneurysm getting bigger
- Radiological follow up for size monitoring.

### **Surgical Intervention**

Surgery should be considered for an AAA **>5.5cm** in diameter, AAA **expanding at >1cm/year**, or a **symptomatic AAA** in a patient who is otherwise fit.

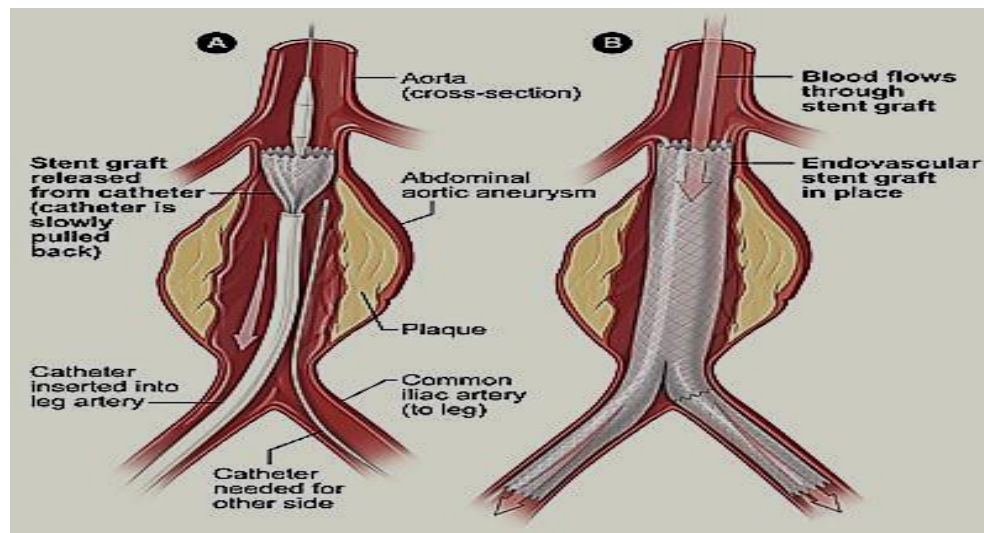
The main treatment options are **open repair** or **endovascular repair**, however both options have similar long-term outcomes.

**I- Open repair** involves a midline laparotomy or long transverse incision, exposing the aorta, and clamping the aorta proximally and the iliac arteries distally, before the segment is then removed and replaced with a prosthetic graft

**II- Endovascular repair** has better short term outcomes, however long term outcomes are better for those undergoing open repair..

Endovascular repair have an improved short term outcome in terms of decreasing hospital stay, yet has a higher rate of re-intervention and aneurysm rupture.

After 2 years the mortality for both procedures is the same, therefore in young fit patients an open repair may be more appropriate



---

**Family: Plasmodidae**

## **Genus: Plasmodium**

### **1- PLASMODIUM AND MALARIA**

- 1- Plasmodium vivax (Benign tertian malaria).
- 2- Plasmodium malariae . (Quartan malaria).
- 3- Plasmodium ovale (Ovale tertian malaria).
- 4- Plasmodium falciparum (Malignant malaria).

#### **Distribution:**

P.vivax is abundant in the temperate zone while P. falciparum is more common in tropical regions. P.malariae is a parasite of subtropical zone. P.ovale is present in West Africa, South America and Asia.

#### **Life cycle:**

The life cycle of malaria is passed in two hosts and has sexual and asexual stages.

- A) Vertebrate host (man) I.H.: where the asexual cycle takes place. The parasite multiplies by Schizogony which may occur inside RBCs called erythrocytic, or in liver cells called exoerythrocytic.
- B) Invertebrate host (mosquito) D.H.: where the sexual cycle takes place. It occurs in stomach mosquito, where male and female gametocytes taken with blood of man start sexual cycle which is called sporogony cycle.

#### **Mode of infection:**

- Bite of infected female anopheline mosquito.
- Blood transfusion.
- Contaminated syringes.
- Congenital infection

#### **A- Asexual cycle (schizogony):**

Human infection begins when a female anopheline mosquito bites man and inoculates the saliva containing sporozoites (infective stage). The sporozoites circulate with the blood and within 30 minutes enter liver parenchyma cells to begin the exo-erythrocytic schizogony.

##### **• Exo- erythrocytic schizogony (pre-erythrocytic stage):**

The sporozoite becomes rounded and changes to trophozoite. The trophozoite (amoeboid in shape) feeds on the liver cells and enlarges. After maturation, the nucleus divides into a large number of nuclei, each takes a piece of cytoplasm round it resulting in the formation of preerythrocytic schizont containing thousands of merozoites. When the liver cells rupture, these merozoites are released in the sinusoids (period between

infection of liver till liberation of merozoites is about 6-11 days). In all four species, asexual multiplication takes place within the liver cells, but with *P.vivax* and *P.ovale* some of the infecting sporozoites enter a resting stage before undergoing asexual multiplication while others undergo this multiplication without delay. The resting stage of the parasite is known as hypnozoite. After a period of weeks or months, reactivation of the hypnozoites initiates asexual division. Fate of merozoites:

- 1- Engulfed by phagocytes and destroyed.
- 2- Re-enter liver cells and repeat the cycle, except *P.falciparum* and *P.malariae* where all merozoites invade RBCs without reinvading liver cells so there is no relapse.
- 3- Enter RBCs and produce blood infection and symptoms of malaria.
  - **Relapse:** A recurrence that occurs after complete initial clearing of the erythrocytic infection and takes place as a result of reinvasion of the red blood cells by parasites from the dormant pre- erythrocytic stage. It occurs in *P.vivax* and *P.ovale*.
  - **Recrudescence:** A recurrence of clinical attacks in patients having low-grade parasitaemia when they become debilitated (occurs in *P.falciparum* and *P.malariae* infections).
  - **Erythrocytic schizogony:**
    - Merozoite entering the red cell forms a loop of cytoplasm having a small chromatin and enclosing a vacuole, called ring stage.
    - The parasite feeds on red blood cell haemoglobin, enlarges and becomes vacuolated developing into trophozoite.
    - Chromatin and cytoplasm of the parasite then break into pieces (6-36) a stage called schizont, (the process is called erythrocytic schizogony).
    - The metabolized haemoglobin appears in cytoplasm of the parasite as yellowish brown granules (called malaria pigments or haemozoin).
    - Other granules appear in the cytoplasm of the infected red cell. They are named Schuffner's dots in *P.vivax* and *P.ovale* infections, Ziemann's dots in *P.malariae* and Maurer's clefts in *P.falciparum* infection.
    - Rupture of parasitized red blood cell releases merozoites which invade new red blood cells to repeat the cycle.

Some merozoites enter the red blood cell to form male (micro) and female (macro) gametes. Now man is infective to mosquito.

### **Pathogenesis:**

The red blood cell invasion requires specific determinants on the surface of the red blood cell such as Duffy blood group antigen in *P. vivax*. The parasite grows inside the red blood cell at the expense of the haemoglobin which is converted into haemozoin pigment. The pigment is engulfed by endothelial cells and deposited especially in the

organs rich in reticulo endothelial cells i.e. the spleen, liver leading to enlargement of the spleen and liver.

The red cells infected with *P. falciparum* develop knobs on their surface, so they adhere together and to specific receptors on the capillaries of internal organs. These act as emboli and block the blood capillaries leading to ischaemia, oedema, necrosis and capillary haemorrhage.

### **Clinical picture:**

1. Prodromal symptoms (influenza - like): Headache, muscle pain, anorexia and vomiting.
2. Malaria paroxysms (clinical attacks):  
The malaria paroxysm occurs at the end of the schizogonic cycle, when the merozoites together with their pigments and residual erythrocyte debris are released into the circulation. This passes as 3 stages:
  - Cold stage (15 minutes ): the patient feels extreme cold and shivers. Skin becomes pale and cyanotic.
  - Hot stage ( 2-6 hours ): Headache and rapid pulse. The temperature is elevated to 40 .Hot dry flushed skin.
  - **Sweating stage:** Profuse sweating. Temperature falls and headache disappears.

Paroxysms are repeated over a period of 2 weeks or more with decreasing intensity then stop Termination of malaria paroxysms may mean elimination of infection. However, in *P.falcipari*.

And *P. malariae* infections, persisting low-grade parasitaemia may be present denoting latent stion: When the patient becomes debilitated paroxysms reappear (recrudescence).

3. Anaemia occurs due to destruction of red blood cells. Merozoites of *P.vivax* and *P.ovale* are to invade only reticulocytes. Meiozoites of *P..malariae* invade only old red cells near the end heir life span. This restricts the infection. However, *P, falciparum* merozoites infect red cells of any age causing severe haemolytic anaemia.
4. Enlargement of liver and spleen: Due to hyperplasia of RES

### **Complications:**

#### **1- In *P. malariae*:**

Nephrotic syndrome: Due to deposition of immune complex on the glomerular wall.

#### **2- In *P. falciparum* (pernicious or malignant malaria):**

- Cerebral malaria: Neurological manifestation such as fever, severe headache, confusion, convulsion and coma.

- Dysenteric malaria: Abdominal pain, vomiting, dysentery and upper gastrointestinal bleeding which may be related to ischaemia of the intestinal wall capillaries.
- Pulmonary oedema: Resulting from fluid retention, cardiac decompensation or anoxia affecting pulmonary circulation.
- Algid malaria: Characterized by rapid development of hypotension, vascular collapse and shock. This syndrome may be the result of pulmonary oedema, massive gastrointestinal haemorrhage or uncorrected dehydration.
- Tropical splenomegaly syndrome: Spleen enlargement associated with high serum IgM.  
This may be due to reduction of suppressor T-cells that control B-cell activation.
- Syncopal form: Sudden death may occur from cardiac failure due to blockage of coronary vessels.
- Black water fever: It occurs usually in patients with repeated attacks, long standing *P.falciparum* or incomplete quinine treatment. It is characterized by sudden intravascular haemolysis with anaemia, jaundice and haemoglobinuria (black urine). It may be the result of the production of autoantibodies to the red blood cell or of circulating antigen - antibody complexes to the cell surface.
- Hypoglycemia: due to impaired hepatic gluconeogenesis.

### **Diagnosis:**

- 1- Character of fever and symptoms.
- 2- Blood film (thin & thick):  
thick film to detect parasites and thin film to identify species. All stages (rings, trophozoites, oocysts and gametocytes) are seen in all types of malaria except in *P.falciparum* where only rings and merozoites are seen where red cells containing trophozoites and schizonts are trapped in capillaries of internal organs.
- 3- Detection of circulating parasite antigens.
- 4- therapeutic test: Administration of antimalarial drugs for 3 days, the symptoms disappear in case of malaria.
- 5- Serological tests (IHAT and IFAT ): especially of value in diagnosis of long standing relapsing infection.
- 6- Use of DNA and RNA probes.

### **tools for treatment of malaria:**

#### Clinical cure:

- Chloroquine,
- Mefloquine

### Radical cure:

- Primaquine: It kills hypnozoites of *P. vivax* and *P. ovale*.

### **III- Prophylaxis:**

- Chloroquine:  
300 mg (2 tablets) / week for 2 weeks before visiting an endemic area up to 6 weeks after leaving
- Pyrimethamine.
- Proguanil.

### **Epidemiology:**

The transmission of malaria parasites in an area depends on:

1. The presence of infected man
2. The presence of anopheles mosquito.
3. Susceptibility of human to infection.
  - Glucose - 6- phosphate dehydrogenase ( G-6-PD) deficient cells are more resistant to invasion by *P. falciparum*. Haemoglobinopathies especially the presence of haemoglobin S are resistant to *P. falciparum*.
  - Duffy blood group negative human erythrocytes in West African blacks and American blacks account for the resistance these people to *P. vivax*.

### **Prevention and control :**

1. Treatment of cases.
2. Chemoprophylaxis.
3. Mosquito control.

In Egypt, malaria is under control. However, it is threatened by *falciparum* malaria from several neighbouring countries especially Sudan where it is endemic.

## **Tissue nematoda (Filarial worms)**

### **Wucheria bancrofti**

**Disease: Bancroftian filariasis, wuchereriosis, elephantiasis.**

**Geographical distribution:** Tropical and subtropical areas e.g. Tropical Africa and Asia, Central and South America. In Egypt, it is present in Kalyobia, Dakahlia, Sharkia, Cairo, Giza and Assuit.

### **Life cycle:**

- **Final host and habitat:** Adults live in lymph vessels and glands of man (no reservoir hosts).
- Microfilariae laid by the female appear in the peripheral blood by night between 10 PM - 2 AM, and gradually disappear by day time (nocturnal periodicity).
- **Diagnostic stage:- Microfilaria** in the peripheral blood at night

- 250 x 8u.
- Smooth body curves.
- Loose sheath and tail end is free of nuclei.
- **Adults** may be seen too.
- **Infective stage:** 3<sup>rd</sup> stage filiform larvae
  - 1.5 - 2 mm x 20u.
  - Slender and cylindrical oesophagus.
  - In the labium of the mosquito vector.
- **Mode of infection:** Mosquito bite and active skin penetration by infective filiform larvae.
- Larvae pass to the lymphatic vessels and nodes, moult twice and grow to maturity in about one year.
- The adult worms are present frequently in the lower limbs, groin and genitalia.

### **Nocturnal periodicity:**

### **Pathogenesis and clinical picture:**

- 1- Asymptomatic cases: in endemic areas, most cases remain, asymptomatic throughout life. Some cases have microfilaraemia without symptoms of the disease.
- 2- Symptomatic cases.
  - a) **Acute inflammatory phase:**
    - **General manifestations:** fever, toxaemia, urticaria and microfilaraemia.
    - **Local manifestations:** filarial or elephantoid fever,.
    - ❖ **Lymphangitis:** The inflamed lymph vessels appear as red, hot, swollen and tender.
    - ❖ **Lymphadenitis:** Enlarged and tender lymph glands.
    - ❖ The lesions usually in the lower limbs and genitalia but may occur in upper limbs.

### **B) Chronic obstructive phase:**

- ❖ **Elephantiasis:**
- ❖ **Rupture of the dilated lymph vessels in the:**
  - Pelvis of the kidney → the urine is milky white
  - Scrotum → chylocele after hydrocele.
  - Intestine → Steatorrhea.
  - Peritoneal cavity → chylous ascites.
  - Thorax → chylothorax.

**Prognosis:** Is good in asymptomatic and acute phase. Poor & bad in elephantiasis.

### **Diagnosis:**

**1. History and clinically:** presence of attacks of lymphangitis and lymphadenitis, elephantiasis, chylocele or chyluria.

**2. Laboratory:**

a) **Parasitological:**

Detection of microfilariae in blood at night (10 PM - 2 AM). They are highest capillary blood (ear lobe or finger).

- Diethylcarbamazine (DEC) provocative test: the individual is given 50 -100 mg DEC and after 45 - 60 minutes the blood sample is examined.

- Fresh blood examination after staining by Giemsa.

**-Knott's concentration technique**

b) **Immunological:**

c) **Blood picture** : Eosinophilia

**3- Radiological** (for adult worms): Ultrasonography, X-ray shows calcified worm, and Lymphangiography.

**Treatment:**

**A) Antifilarial drugs:** Diethylcarbamazine (DEC or Hetrazan): Antihistaminics and corticosteroids Ivermectin and albendazole, and Combination of DEC and Ivermectin

**Prevention and control:**

Control of mosquito vector, Mass treatment, and Chemoprophylaxis: DEC is given at monthly intervals in endemic areas.